The EYE, EAR NOSE & THROAT MONTHLY

Volume III MARCH, 1924 Number 2

Div. 43
U. S. Patent Office
MAR 8 1932
Div. 43

Contributors

F. E. BRAUCHT, M. D., M. D. S.
Fremont, Neb.
J. E. BRAUNSTEIN, M. D.
Brooklyn, N. Y.
HIRAM BYRD, M. D.
Ocala, Fla.
WM. H. GESTWEIT, JR., M. D.
San Diego, Cal.
ABRAHAM R. HOLLENDER, M. D.
Chicago, Ill.
SYDNER D. MAIDEN, M. D., M. S.
Council Bluffs, Ia.
J. G. PARSONS, M. D.
Sioux Falls, S. D.
SANDERS M. PAYNE, M. D., F. A. C. S.
New York City
ARTHUR J. WAGERS, M. D.
Philadelphia, Pa.
W. D. WITHERBEE, M. D.
New York City

THE PROFESSIONAL PRESS INC.
CHICAGO, ILL.

Entered as second class matter October 20, 1922, at the post Office at Chicago, Illinois, under the Act of March 3, 1879
Subscription: One Year, $3.00. Canada, $3.50. Foreign $4.00. The Professiona Press Inc., Publishers, 17 N. Wabash Ave., Chicago, Ill, Issued Monthly.
Copyright 1924 by the Professional Press, Inc., All Rights Reserved.
Postmaster, if undeliverable, return postage guaranteed.

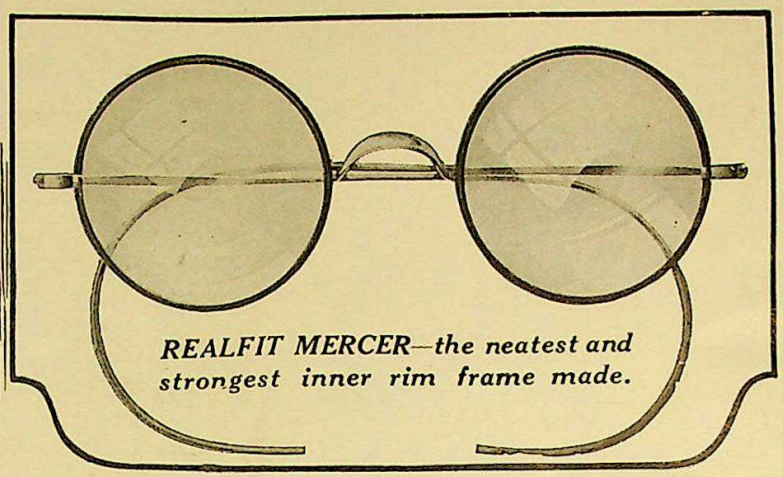

REALFIT MERCER—the neatest and strongest inner rim frame made.



"There's a Frame that you can BEND!"

That's the shop man talking—the way he always talks about the Realfit Mercer.

He has had many a frame break while he was trying to bend it—but never a Realfit Mercer. He has seen scores come back from the customer, broken the first day out of the shop—but never a Realfit Mercer. The shop man knows from experience that the bridge union—the weakest part of most frames—is the strongest part of the Realfit Mercer. He knows that it will stand up under any amount of bending. He knows that it will not lose its temper in fitting so that the first jar it gets will break it.

Not only does he know that, but he knows, too, that the eye wires of the Realfit Mercer are absolutely accurate in size—that when he puts a 40mm lens into a 40mm frame it will fit exactly right. He knows that the zylonite covering can be removed if necessary—and still hold its form. These are a few of the finer points of the Realfit Mercer that painstaking manufacturing methods have developed, and that observing shop men have been quick to appreciate.



Ask to see samples of the Regular Realfit Mercer and of the Heavy Realfit Mercer No.557. Become familiar with their superior features yourself.

NEW JERSEY OPTICAL COMPANY

91 RUNYON ST. NEWARK, N. J.

Busy specialists appreciat the speed from the Castle 1413 sterilizer

WHEN asked what features commended CASTLE equipment to the ear, eye, nose and throat specialist, whose examination room is reproduced herewith, his nurse said that the speed with which sterilization was obtained made CASTLE equipment seem indispensable. The gas sterilizer the specialist formerly had was "always going out" and smelled offensively. The specialist's present equipment is electric.

The automatic cut-off feature of No. 1413 prevents going dry. Three-heat control switches.

Write for catalog of complete information about this and other Castle Sterilizers.

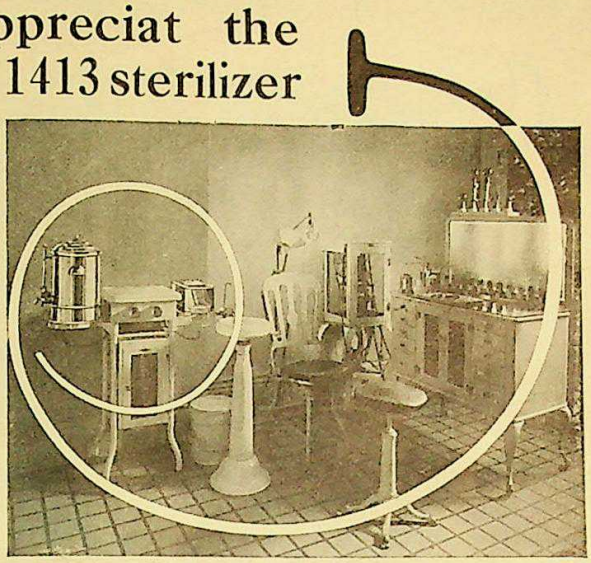

One of three, eye, ear, nose and throat specialists' offices equipped with Castle sterilizers at 303 Alexander Street, Rochester, New York.

CASTLE

Complete line of Physicians', Dental, Hospitals and Bacteriological Sterilizers

WILMOT CASTLE CO., 1180 University Ave., Rochester, N. Y.

CASTLE

"Every office needs a good sterilizer"

Oesophageal Stricture Dilators

And

Radium Applicators For Use In The Oesophagus

The set of instruments illustrated here is the result of years of careful experimentation on the part of Dr. Plummer, (Mayo Clinic), and in its present form is giving very satisfactory results.

The set consists of sixteen conically shaped olives, arranged in size from 15 to 45 French scale, Fig. 1, a carefully shaped whalebone staff with flexible spiral end which permits of introduction over a braided silk cord.

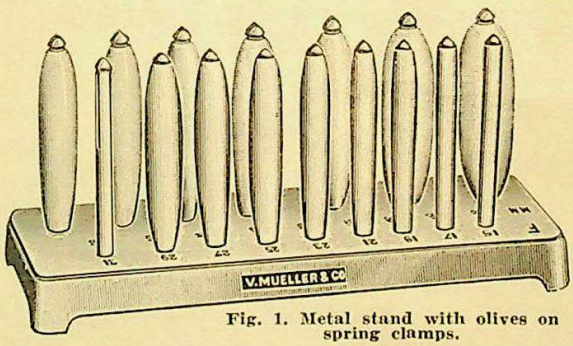

Fig. 1. Metal stand with olives on spring clamps.

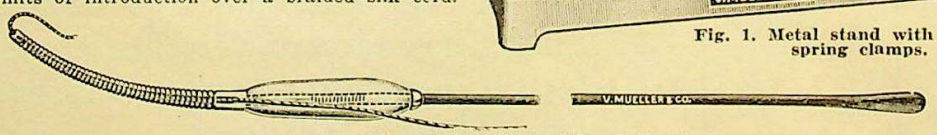

Fig. 2. Whalebone staff with flexible spiral end

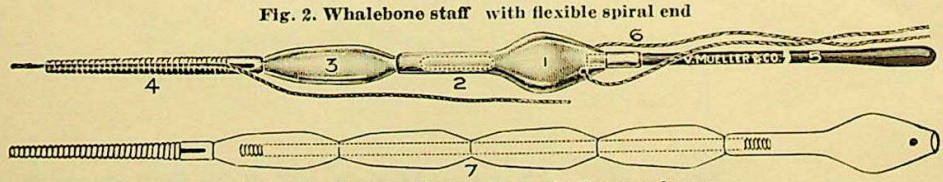

Fig. 3. Radium applicator for use in the oesophagus

This instrument was devised by Drs. Plummer and Vinson (Mayo Clinic), for the purpose of applying radium in the oesophagus and by its means the surgeon is assured that the radium application will be made on the site of the lesion, because when in position it is impossible for the radium capsule to move either up or down.

Figs. 1 to 6 indicate the parts of the instruments as assembled for actual use, Fig. 2 showing the radium capsule in dotted lines safely lodged in Filter Fig. 1. Fig. 7 shows the outfit assembled in order to keep all of the parts together when not in use. Two additional olives of smaller size are now furnished with the outfit.

Made by V. MUELLER AND COMPANY, Ogden Avenue, Honore and Van Buren Streets, Chicago, Illinois



The Geneva Ophthalmoscope

Is the Efficient Method of Diagnosing a Case

YOU AVOID COSTLY ERRORS AND SAVE TIME!

THIS instrument presents a new scientific method of diagnosing which will lend vital assistance to the oculist that can be had in no other way. A decided advantage over the hand instrument lies in the working distance of this instrument, with which it is not necessary to approach close to the patient's face.

Send for our booklet today.

Geneva Optical Co.

Wholesale Prescription Specialists
Since 1875

CHICAGO ST. LOUIS DES MOINES
MINNEAPOLIS CINCINNATI MINOT N. D.

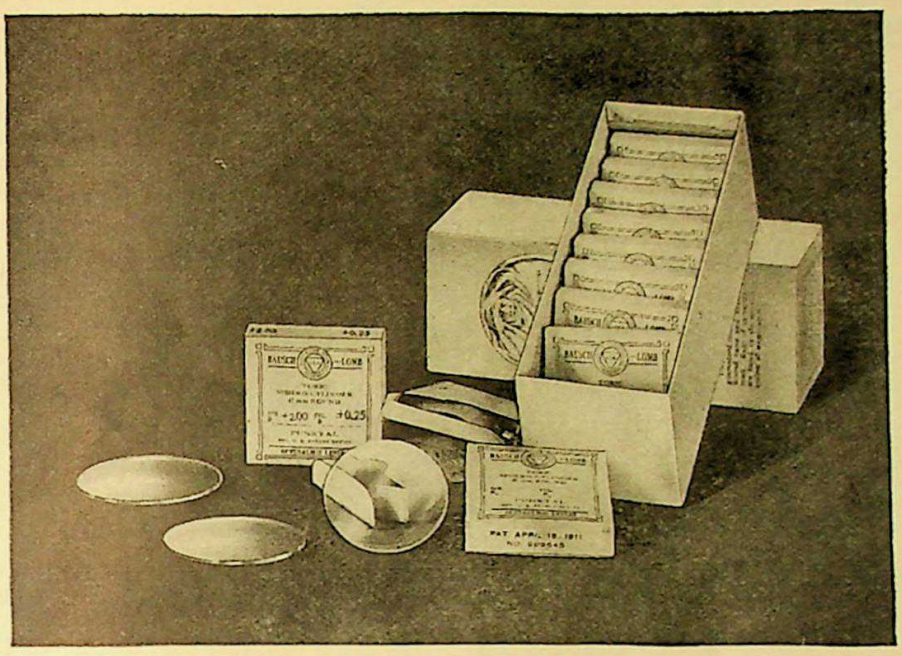

Nine Reasons for Punktal Popularity

1. Punktals give a wider visual angle than any other lens.
2. Punktals are "custom made"—they are individually computed for each power.
3. Punktals are surfaced on both sides by the Bausch & Lomb Optical Company only.
4. Punktals are light in weight.
5. Punktals are as easily prescribed as ordinary torics.
6. Punktals are handsome in appearance.
7. Punktals will increase the satisfaction of your patients.
8. Punktals will enhance your professional reputation.
9. Punktals are carried in stock by Riggs Optical Company, so that practically any prescription can be filled immediately.

PLEASE WRITE FOR PUNKTAL LITERATURE

Riggs Optical Company

Strictly Wholesale

Omaha	Salina	Pittsburg, Kans.	Butte	Boise
Fargo	Wichita	Council Bluffs	Tacoma	Ogden
Denver	Lincoln	Cedar Rapids	Seattle	Pueblo
Madison	Appleton	Sioux City	Spokane	Mankato
Hastings	Kansas City	Waterloo	Los Angeles	Portland
Green Bay	Great Falls	Iowa City	Oklahoma City	Pocatello
Fort Dodge	Sioux Falls	Quincy	Salt Lake City	San Francisco
		Reno		

Please mention the Eye, Ear, Nose and Throat Monthly.

Safety Lies in Quality ---Advise ULTEX

The final expression of a careful, accurate, conscientious refraction can be had only in lenses carefully, accurately and conscientiously made. The Ultex Onepiece Bifocal is the consummation of years of study and effort and into its manufacture goes the highest precision and mechanical skill.

The professional man who advises Ultex when bifocals are indicated knows that the patient will receive exactly the comfort and satisfaction desired. There is no substitute for Ultex any more than there is a substitute for a careful and proper examination.

Write today for a copy of the third edition of "Bifocals" an authoritative work on the development and manufacture of Bifocal lenses. It is sent only upon application.

ONEPIECE BIFOCAL LENS COMPANY

Manufacturers of Quality Optical Products

INDIANAPOLIS, IND., U. S. A.



DOUBLE END SUBMUCOUS DISSECTOR

By Dr. Marvin Jones, New York, N. Y.

The elevator is designed for facilitating the dissection of the mucous membrane around deflections and spurs, especially near the maxillary ridge. Price $2.75.



FRONTAL SINUS CANULA WITH OBDURATOR

By Dr. Robert Myles, New York, N. Y.

The canula represents the original Myles' frontal sinus canula and upon repeated requests from the profession, we have fitted this with an obdurator to the end that introduction into the natural opening of the sinus is facilitated and additional rigidity added to the canula. The hubs are made to fit either the universal screw thread syringe or with a Luer fitting. The outer canula is pure silver and the obdurator, nickel silver. Price $2.75.



ORAL TREPHINE

By Dr. John Guttmann, New York, N. Y.

This instrument was devised by Dr. Guttmann for opening the ear drum where it is desirable to maintain drainage longer than is established by use of the paracentesis knife. The shank of the instrument is sufficiently long to pass well through the ear specira and the distal end is fitted with two interchangeable blades of different sizes. Price $6.50.

OUR 1924 CATALOGUE WILL SOON BE READY FOR DISTRIBUTION. A COPY WILL BE SENT ON REQUEST.

GEORGE TIEMANN & COMPANY

107 East 28th Street **New York, N. Y.**

ANNOUNCING
Three New Worth-While Books!

INTRANASAL SURGERY
by
Drs. F. J. and J. A. Pratt
1924
Illustrated with 195 Halftone Engravings
Price $5.00 Net.

OPHTHALMIC SURGERY
by
Dr. Josef Meller
Edited by
Dr. William M. Sweet
Third edition, enlarged and greatly improved
With 219 original illustrations
Price $5.00 Net.

PERIMETRY
Principles and Practices
by
Luther C. Peter, M. D.
Second edition, thoroughly revised
Illustrated with 161 engravings and 5 colored plates
Price $4.00 Net.

We carry one of the most complete lines of Eye Text Books, Ophthalmic Equipment and Artificial Eyes.

Correspondence Solicited.

McIntire, Magee & Brown Company
723 SANSOM STREET, PHILADELPHIA

Service Branches for Your Convenience.

1317 New York Ave., N. W.
Washington, D. C.

9 & 11 Nesbitt Court,
Wilkes-Barre, Pa.

It's Sharp — BARD-PARKER KNIFE — It's Sharp

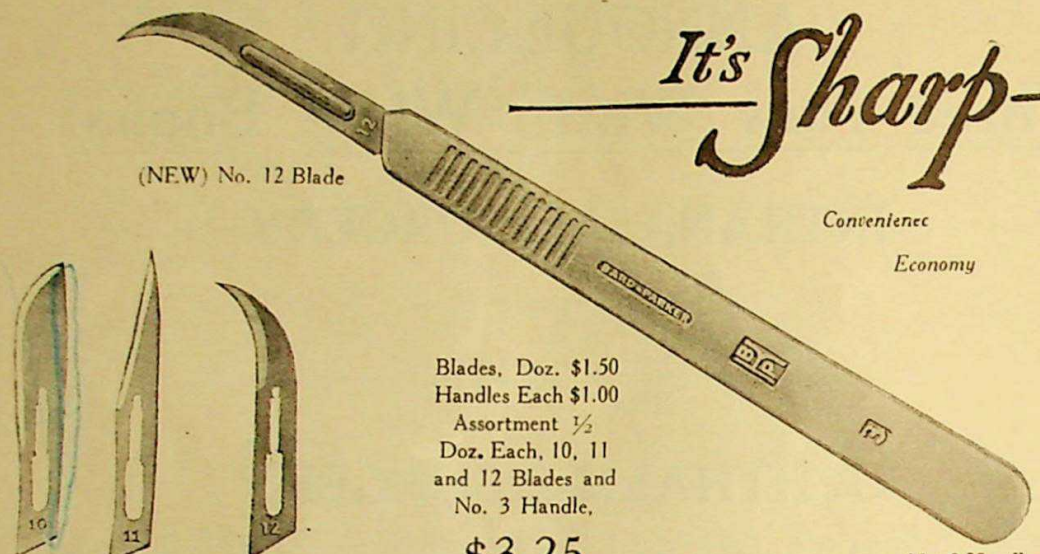

(NEW) No. 12 Blade

It's Sharp

Convenience

Economy

No. 10 No. 11 No. 12

Blades, Doz. $1.50
Handles Each $1.00
Assortment ½ Doz. Each, 10, 11 and 12 Blades and No. 3 Handle,

$3.25

No. 3 Handle

ASK YOUR DEALER

Bard-Parker Co., Inc., 150 LaFayette St., New York City

SPECIALIST'S TREATMENT CASE



This case has been found to be very useful on the specialist's treatment stand in the hospital ward, or can be carried in the bag to the home.

There are nine one-ounce glass-stoppered bottles, a small cotton reservoir, and a beakette for individual applications of cocain, argerol, etc. There is a space between each bottle for droppers, applicators, etc. Price, $10.00.

KLOMAN INSTRUMENT CO. 1114 Fourteenth St. Washington, D. C.

CONTENTS.

CONTRIBUTED ARTICLES—

Acute Mastoiditis, Apparently Primary, in An Infant of Seven Months. By Arthur J. Wagers, M. D. 73
Electrical Modalities in Our Specialties. By F. E. Braucht, M. D. 75
More About Meckel's Ganglion. By Hiram Byrd, M. D. 77
Iritis Tuberculosa. By J. G. Parsons, M. D. 80
Suction Tonsillectomy. By J. E. Braunstein, M. D. 82
Sequelae of Trachoma. By Sanders M. Payne, M. D., F. A. C. S. 86
The Problem of the Stammering Child. By Abraham R. Hollender, M. D. 89
Brain Abscess and Chronic Suppurative Osteomyelitis, Associated with Mastoid Disease. By Sydner D. Maiden, M. D., M. S. 93
Principles of X-Ray Therapy in Chronic Pharyngitis and Tonsillitis. By W. D. Witherbee, M. D. 99
An Unusual Nasal Polyp. By Wm. H. Gestweit, Jr., M. D. 103

EDITORIALS 93

ABSTRACT OF PROCEEDINGS—

Royal Society of Medicine, Sections of Ophthalmology and Oto-Laryngology 107

CLINICAL DIGEST 110

AMONG THE PROFESSION 114

Butyn **According to a prominent opthhalmologist:**

"On account of its instability, toxicity, dilating effect on the pupil, drying effect on the corneal epithelium, and its danger of causing glaucoma, cocaine is best supplanted by some of the newer products of synthetic chemistry.—Butyn is the most important rival to cocaine that has yet appeared.—Its value has been proved by careful investigation." (Dr. Chas. P. Small, in Vol. 3 of the Practical Medicine Series, 1922, pages 180 and 181.)

Butyn is obtainable in 2% solution, without narcotic blanks; also in tablets and powder. Leaflet sent on request.

THE ABBOTT LABORATORIES

4739 RAVENSWOOD AVENUE, CHICAGO

31 E. 17th St. New York | 234 Central Bldg. Seattle | 559 Mission St. San Francisco | 420 S. San Pedro St. Los Angeles

TORONTO BOMBAY

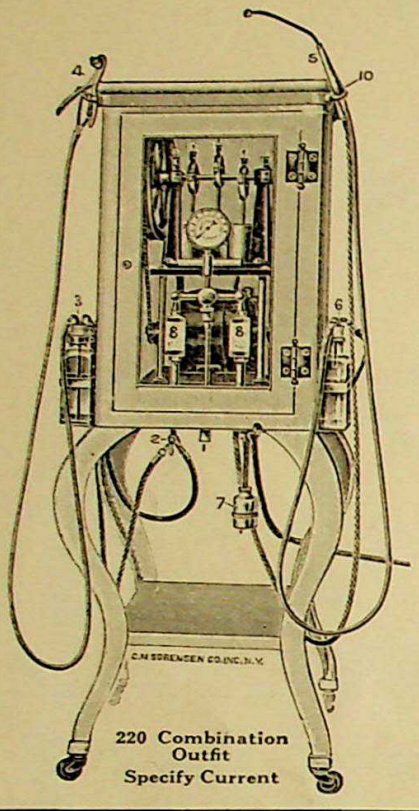

220 Combination Outfit
Specify Current

C. M. SORENSEN CO., INC.

444 Jackson Avenue
Long Island City, N. Y.
Tel. Astoria 6740

Builders of

PROFESSIONAL
and
SPECIALISTS'
EQUIPMENT

Detail Circulars mailed upon request

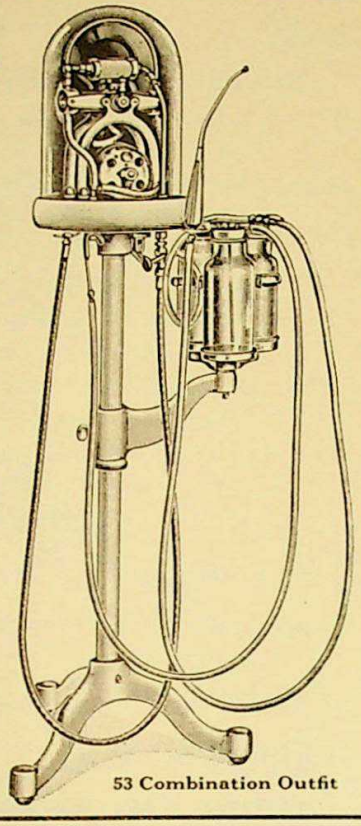

53 Combination Outfit

A DISTINCT ADVANCE NOT A MINOR IMPROVEMENT IN TONSILECTOMY

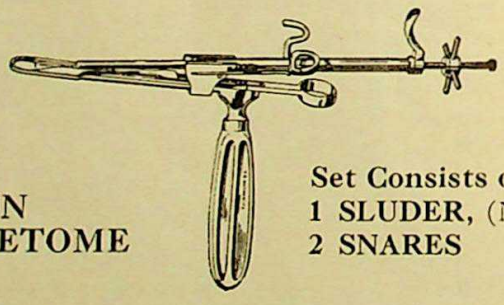

The
BRAUN
SNARETOME

Set Consists of
1 SLUDER, (Modified)
2 SNARES

As shown, the snare is engaged to the tonsilotome part with the wire loupe encircling the fenestrum. After tonsil is engaged in tonsilotome and dull blade is pushed home, the snare is drawn up securely engaging tonsil and automatically disengaging the tonsilotome part which is then removed from the mouth and engaged to the second snare for operation on the other tonsil in the same way.

Both tonsils are engaged in snares before any bleeding takes place to obscure the field and may be removed by means of the screw as rapidly or as slowly as may be desired.

Barbs on the end of snare canula impale tonsil—no forceps required—no danger of tonsil being swallowed.

Simple technique—minimum reaction.

SEND FOR REPRINT

E. B. MEYROWITZ SURG. INSTRUMENTS CO. 520 5th Ave., New York

Complete Refraction at Your Finger Tips— The Genothalmic Unit

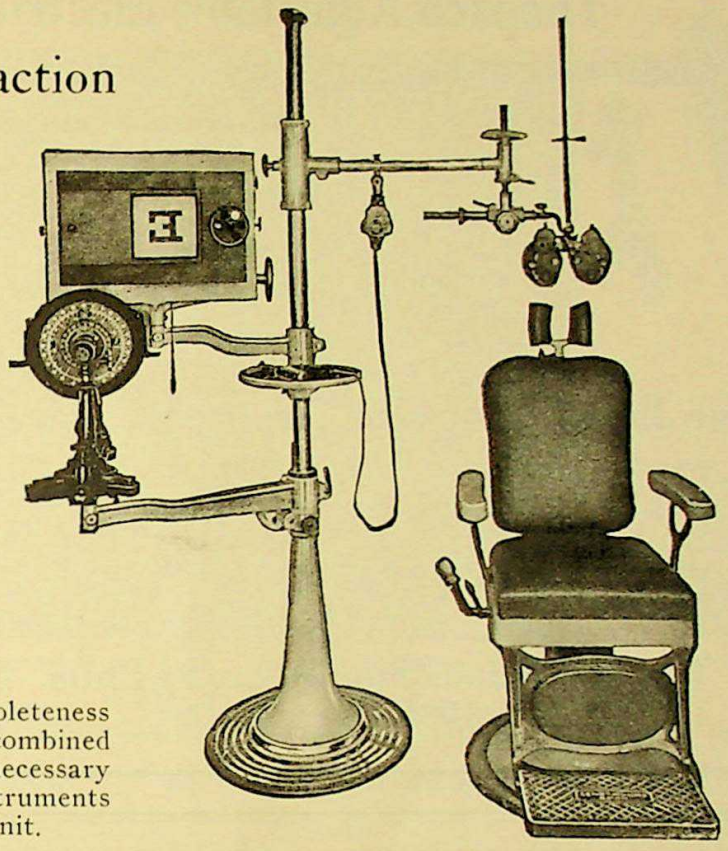

Convenience, completeness and accuracy are all combined in a grouping of necessary Refracting Room Instruments in the Genothalmic Unit.

No running around the office from instrument to instrument—shifting of the patient from place to place—loss of time—incomplete examination—tiresome and laborious routine.

At your finger tips, in the Genothalmic Unit, is the means for a complete standardized routine examination. The patient remains seated in the one chair during the entire procedure. The operator remains in position before the patient and merely swings the ophthalmometer and refractor into place for use. The Multiple Test Chart is at hand and controllable without the operator changing position. The diagnostic instruments with city current are all ready for use in their regular routine.

You will do better work with the Genothalmic Complete Unit. Your patients will be better satisfied.

Detailed information on this invaluable grouping of instruments will interest you. Write for it.

General Optical Company, Inc.

Manufacturers

Mount Vernon, N.Y.

San Francisco Chicago Philadelphia

Thepsco Adjustable Electric Wall Bracket (New)

C 3534

Has a vertical as well as a lateral adjustment at the wall fitting, and a spiral adjustable arm. Highly polished and nickel plated.

C 3534 Thepsco Adjustable Wall Bracket, complete with 8 ft. connecting cord, frosted Stereophicon Lamp and Universal Condenser, as illustrated, **$11.50.**

The Brown Specialist Treatment Cabinet



A-135

Especially designed to meet the requirements of the Nose and Throat Specialist.

White enameled, with Monel Metal top (as illustrated), or with Plate Glass or Opal Glass top as desired. Has a nickel plated rack to hold 15 treatment bottles and 6 atomizers; also a white enameled instrument tray, transferable to either side of the Cabinet.

A 135—White Enameled Specialist Cabinet, 30" wide, 16" deep, 32" high, complete with W. E. Tray and 15 assorted solution bottles, amber, blue and crystal, **$85.00.**

Can be furnished in Mahogany or French Gray Finish at an additional cost of $7.50.

The Physicians Supply Co. of Phila.

N. W. Cor. 16th & Sansom Sts., Phila.

Write for our latest Catalog of Eye, Ear, Nose and Throat Instruments

MAKING ARTIFICIAL HUMAN EYES

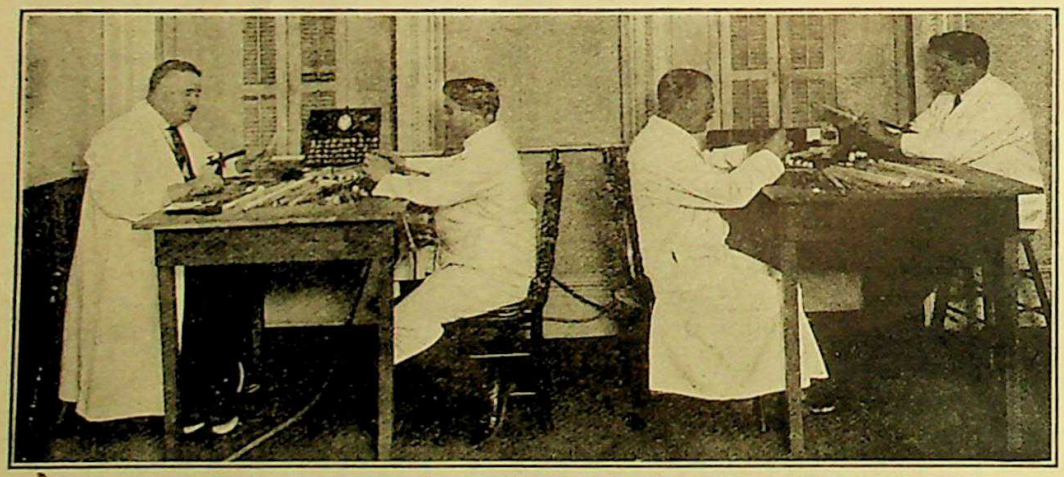

Our staff of expert eye makers. From left to right they are Max Kohler, Max Heinz, Sept. Danz and Arno Kohler

Specialists Since 1893 in making Artificial Human Eyes to Order

No connection with any other House

KOHLER & DANZ, 129 East 23rd Street, New York

Selection sent on Request

Please mention the Eye, Ear, Nose and Throat Monthly.



EYE SIZES

Are of importance to you, not alone in the accuracy of the sizes, but that you are enabled to secure the particular size to meet your requirements in whatever pupillary distance is necessary in addition to obtaining bridge dimensions in sufficient variety to satisfactorily answer your fitting problems.

You will note that all Princeton eye sizes are accurate and that the lens grooves are cut with the utmost precision in regard to depth, angles and the outside bevels.

Such details combine with many other features to make Princetons the frames acknowledged as dependable in every particular and from every standpoint.

Trade Improvement

Through Co-operation

BAY STATE OPTICAL CO.

ATTLEBORO MASSACHUSETTS U. S. A.

KRYPTOK LENSES

BACKED for years by the expert recommendation of leading optical specialists everywhere, Kryptok Glasses are being worn with perfect satisfaction today by millions of men and women who require corrections for both near and distant vision.

The universal preference, when bifocals are needed, is now, more than ever—

KRYPTOK GLASSES

The Invisible Bifocals

The EYE·EAR·NOSE and THROAT
MONTHLY

Acute Mastoiditis, Apparently Primary, in an Infant of Seven Months

By Arthur J. Wagers, M. D., Philadelphia, Pa.
ASSOCIATE PROFESSOR OF LARYNGOLOGY, POST GRADUATE SCHOOL OF THE UNIVERSITY OF PENNSYLVANIA.

The title of this report suggests at once that there is some question as to whether or not the mastoiditis found was the result of a primary or secondary infection.

The history in the case is briefly as follows: The baby, W. B., Jr., was referred to the hospital by Dr. B. P. Steele for such treatment as might be deemed necessary. Questioning the mother who brought the child, it was learned that there had been no previous illness other than a "cold." For two weeks previous to admission the child had been fretful, showed slight elevations of temperature and by more or less constant movement of the hand in the direction of the left ear had attracted attention to that organ. It was not until four or five days before coming to the hospital that swelling was observed behind the auricle. This swelling had rapidly increased. At no time had there been any discharge of pus into the external auditory canal.

Examination on admission revealed the following conditions: Child was well nourished, somewhat fretful, with a temperature of 99.3 Attempting to make an otoscopic examination of the external auditory canal and membrana tympani, it was at first thought that the canal was practically closed by swelling. The apparent swelling was found to be a hardened mass of cerumen lying against the posterior wall. When this mass of cerumen was removed the entire canal was found to be free of swelling and the drum membrane with all its landmarks clearly visible. The only variation from the normal was a slight duskiness of the drum. Inspection failed to indicate a suppurative otitis media.

Behind the auricle, the entire mastoid region was found to be markedly swollen and fluctuation easily elicited. There was no question as to the presence of pus within the swollen area. What was the actual condition present—a primary subperiosteal abscess or a subperiosteal abscess secondary to infection within the mastoid process? The former seemed much more probable since because of the apparent non-suppurative middle ear and the entire absence of swelling or bulging of the posterior and superior walls of the external auditory canal, the presence of a suppurative mastoid was very much doubted. But one learns to expect the unexpected in mastoid diagnosis and it was with this thought in mind that I prepared to operate—first, on an abscess outside the mastoid cortex, and second, on the mastoid itself should the first step uncover indications for the second.

Operation.—Under general anesthesia the usual postauricular mastoid incision was made, exposing and draining the expected abscess. The soft parts were retracted in order to expose the mastoid cortex. After rather a prolonged and seemingly fruitless search for a perforation of the cortex, a minute drop of pus was finally observed pushing its way through a slightly roughened area of the bone posterior to the external auditory canal. This served to remove all doubt and the cortex was opened, revealing a mastoid process in which there was almost complete breaking down of the bony cells and the cavity was filled with pus and granulation tissue. All of this was removed as in any simple mastoid operation. It was then deemed advisable to incise the ear drum in order to remove any doubt as to the question of suppuration in the middle ear. This was done. No pus was found at this time nor during subsequent treatment. The mastoid wound was dressed and treated in the usual manner and recovery took place without complications.

Was this a case of primary mastoiditis without a pre-existing otitis media? It seems to me that an answer based on the known facts in the case is bound to be in the affirmative. Text books refer to primary mastoiditis as a "rare condition." Hempstead, in June, 1923, reports three cases seen in the Mayo Clinic and in the same paper states that a careful review of the English and

American literature reveals but 26 reported cases since 1915.

There are those who hold that infection of the mastoid never occurs as a primary condition, with the possible exception of the rare case in which it is believed the infection has been carried by the blood stream directly to the mastoid region.

There is a great deal of theorizing—a great deal of assumption connected with the study of these cases. We assume, and the assumption appears so reasonable as scarcely to require proof, that infective bacteria reach the middle ear from the naso-pharynx by way of the Eustachian tube. We know that the surface of the mucous membrane lining the Eustachian tube and the middle ear cavity is covered with siliated epithelium, and we are taught that the movement of this ciliated epithelium tends to propel all matter thrown on its surface from within outward—that is, from the middle ear toward the pharyngeal orifice of the tube. I think we may accept this point as an established fact. But how, then, does the germ in the naso-pharynx ever find its way to the middle ear? In order to answer the question, we are obliged to assume that either as a result of general systemic disturbance as in scarlet fever, measles, influenza, etc., the motility of the cilia is for the time arrested, thus removing the principal source of interference to the passage of organisms through the tube or else we must conclude that the middle ear invasion is accidental or the result of external forces sufficient to overcome the natural opposition afforded by ciliary movement.

In passing, it might be asked why infective bacteria do not sometimes establish themselves and form an abscess within the Eustachian tube. It is quite possible that infection does occur within the tube at times, but because of the adequate drainage provided by the tube itself it is not to be expected that an abscess would be formed of such proportions as to become clinically evident.

Whatever may be the facts concerning the passage of infective germs through the tube, certain it is that in numerous instances they do succeed in reaching the middle ear cavity and there initiate inflammatory reaction. We may reasonably assume that the swelling incident to inflammation of the mucous membrane is sufficient to effectually close the middle ear outlets, on the one hand by way of the Eustachian tube and on the other by the aditus ad antrum leading to the mastoid cells, thus confining the subsequent suppurative process to the middle ear until such time as an artificial outlet is formed, either by spontaneous rupture or by incision of the membrana tympani.

It is taught by many that in every case of acute suppurative otitis media there is more or less involvement of the mastoid. This may be true as far as the congestive stage of inflammation is concerned, but certain it is that the suppurative stage is but seldom reached in the properly treated case of suppurative otitis media. To explain suppuration within the mastoid in the usual case in which it is clearly secondary to a suppurative otitis media, we assume that the barrier produced by swelling in the aditus was not sufficient to prevent the passage of the infective agents from the middle ear. If we are correct in the assumptions so far expressed, is it unreasonable to assume that there may be an occasional instance in which the infective germ is able in its progress to overcome the obstacles encountered, not only in the Eustachian tube, but in the middle ear as well, and eventually find its way into the cellular region of the mastoid process before finding conditions suited to the establishment of an inflammatory reaction which is to result in pus formation?

If we can accept such a course of reasoning as representing a fair conception of what actually takes place, then, in the case herein reported, it is not difficult to explain the absence of pus in the middle ear as due to the fact that when inflammation occurred within the mastoid, the consequent swelling in the antral region was sufficient to prevent the return of the infective agent to the middle ear. Finally, if there can be any doubt as to the order of infective process as is implied in the title of this report, that doubt arises only from the fact that the condition was not under our personal observation from the onset of the trouble and it is possible that a mild suppuration in the middle ear may have subsided before the patient was sent to the hospital. At the time of admission and operation it was unquestionably a case of a suppurative mastoid without a suppurative middle ear.

Read before the Philadelphia Laryngological Society on Feb. 5, 1924.

Remarks on Nystagmus

Geo. W. Mackenzie, in the Annals of Otology, Rhinology and Laryngology, summarizes as follows:

"Undulatory nystagmus is an involuntary to and fro movement of the eyes. This to and fro movement occurs with equal rapidity. It results from visual defects, especially central. The lesion responsible for the visual defect occurs in early life or even during intrauterine life.

"Rhythmic nystagmus, like the undulatory form, is involuntary to and fro movement of the eyes, but unlike the undulatory, the to and fro movement occurs with unequal rapidity; in other words, the movement in one direction is comparatively slow while the return movement is rapid."

Undulatory nystagmus may be inhibited by a strong effort of the will of the patient. Rhythmic nystagmus can not be inhibited by any effort of the patient.

Electrical Modalities in Our Specialties

By F. E. Braucht, M. D., M. D. S., Fremont, Nebraska

READ BEFORE THE SIOUX VALLEY EYE AND EAR ACADEMY AT SIOUX CITY, IA., JAN. 23, 1924.

In the past few years we have heard much of the value of electricity in treating disease. While electricity is an old and valuable remedy, and I believe indispensable, yet there is a reason for this recent publicity. First,—the discovery of the X-ray and the high frequency currents. Second, —Commercialism; the systematic advertising of the manufacturers of electro-therapeutic appliances. Third,—Experience during and after the war demonstrating its surpassing usefulness. To the uninitiated I would offer a word of warning: Exercise great care in the choosing and purchas- dealers, the truthfulness of whose claims can be with established and reliable manufacturers and ing of electro-therapeutic apparatus. Deal only relied upon. Before you buy get the advice of your co-laborers in the profession who view the matter from your angle and know just what is suited to your special requirements.

The character and quality of equipment used in this class of work is a most important factor in its success or failure. The highest skill on the physician's part may be annulled by poor apparatus. It is also very expensive, especially since the war. (Let us hope that prices will take a drop in the near future.) It is desirable, therefore, that you do not buy a lot of equipment that you find later you cannot use.

Electro-therapeutics is no longer in an experimental stage, but is becoming more and more firmly established on a firm scientific footing as a branch of medicine and to those that know it is no longer "by guess and by God" that they apply it, and its results are sure. Electricity has its uses and limitations. It is not a cure-all, but when scientifically applied in selected cases it will do things that nothing else will, and in some it will do them better than other methods. The chief danger in the use of electro-therapeutics is not the agent itself, but in the person using it. If ignorantly or carelessly applied, it may, and often does, do harm and brings disappointment, whereas if rightly and intelligently used, it gives uniform satisfaction and brings success. It is an axiom that a power for good when rightly used is as great a power for harm when wrongly used in proportion to its potential, and this applies strongly to electricity. It must not be applied by guess, as its laws are unchanging and must be understood just the same as any modality or substance.

A correct technique is everything. There are many in the profession that seem to think a few apparatus and some directions are all that is required to practice electro-therapeutics. There is just as much sense in this as to think that all that is required to make a doctor is a stock of drugs and some instruments. It is essential to understand the physics, chemism and physiological effects of electricity as it is of any other method of treatment. A wise discrimination through the exercise of sound judgment brings success to therapeutics, and the day is not far distant when the true physician will not be hampered by a limitation of schools, pathies, isms or narrow dogmas, but will be like the bee—gather honey from all the flowers, appropriating and using only the best from each that which will relieve or cure most quickly, pleasantly and safely, whether it be drugs, or no drugs at all, baths, massage, electricity, suggestion, sunshine or moonshine.

The doctor who is not posted in electro-therapeutics will seldom see any indications for its use, while the man that is well acquainted with its properties and power will be always finding cases in which it can be applied with great advantage, as there is scarcely any limitation to its varied usefulness.

After nearly thirty years of study and use of electro-therapeutics we think we can speak with some precision on the subject.

This brief paper cannot be exhaustive, but only suggestive, with the hope of stimulating interest and a desire in those who do not use it to get the knowledge and get into the game.

In catarrhal deafness there is no other remedy or method that will give such uniform results. You who have not tried it will be most agreeably pleased at your results. In these cases do not leave off anything you have found of benefit previously, but do not neglect the electricity. My modus operandi is about as follows: Of course you always treat the patient each one as that case may need. In these cases there is nearly always more or less alkalosis of the ossicles, so give the negative galvanic current, 20 to 25 m.a., for 10 minutes with the small electrodes over the ears and the indifferent electrode on the back of the neck or chest, any convenient place. The negative galvanic softens fibrous tissue and the leucocytes carries away the debris. This is following by diathermy for five to ten minutes. The same small ear electrodes are used and must be kept well wet. If the patient complains of any pricking, use a medicine dropper and wet the pads of gauze or cotton. The indifferent electrode is held in the hands as this causes the flow of the current

in the general direction of the course of the Eustachian tubes. This is the anto-condensation handle. The heat generated by this current increases the blood supply and thus calls more leucocytes to the field, and augments the effect of the galvanic current previously applied, and we believe the rapid oscellations of the current has no small effect for good on the obtuned auditory nerve and the cellular tissue which has been softened previously by the galvanic current. The spark gap is barely opened and a D'Arsonval current, as warm as the patient can comfortably stand, is delivered the required time. This is followed by the sinusisdol current comfortably strong for three minutes.

This is further supplemented by the use of the pneumatic vibrator over the ears to shake up the timpanum and ossicles. Also the vibrating Politzer is used in each nostril to open the Eustachen tubes and vibrate the parts from this point.

Nasal sprays and atomizer solutions and throat applications are not neglected. Treat every day until the hearing is normal or ceases to improve, then every other day for two weeks, then once a week for a month, then once a month for the next two or three years. At any time the difficulty seems to flare up, daily treatment should be given again until it subsides.

Otosclerosis and internal ear deafness are treated in practically the same way. Waggoner recommends the Tesla current instead of the D'Arsonval, as he thinks the former has more decided effect upon the auditory nerve on account of its higher voltage and thus greater speed of the current.

Chronic Tumefacting Rhinitis.

The main object in this condition is to tone the musculature of the dilated vessels.

The positive galvanic current contracts blood vessels and so also does adrenalin. But here we must keep someone at home in the mental dome, so as not to overdo the matter and get a reaction that undoes all we have accomplished in the shrinking. To avoid this use a current of two to five m.a. and a solution of adrenalin of 1 to 10,000. Take a long nasal electrode. I have had one made for the purpose; wrap it with a thin layer of absorbent cotton and wet it with the adrenalin solution, then carefully place it in the nostril against the tunefied turbinates and turn on the positive galvanic current until the milliamperemeter registers two m.a.; after a moment you may increase the current one or two m.a. After three minutes turn off the galvanic current and treat with the sinusoidol current of strength comfortable to patient for two or three minutes. We place the indifferent electrode on the back of the neck. In this treatment you not only get the cataphoric action of the adrenalin but also the oxy-chloride action of the copper that is carried into the tissues by the current.

Treat daily until the turbinates are normal, then test the secretions with litmus paper; if acid give negative galvanism daily until the secretions are neutral or nearly so. If this precaution is not taken the condition will soon return.

Chronic Hypertrophic Rhinitis.

This is a condition of lowered tissue resistance with a proliferation into the tissue of connective tissue.

Treat these cases with the negative galvanic current of two to four m.a. strength for five minutes, having the electrode wrapped with a thin layer of absorbent cotton and wet with a solution of Potassium Iodide V grains to the ounce. Follow this, as in the tumefaction cases, with the sinusiodal current of comfortable strength for three minutes.

The following day apply the cotton covered electrode, soaked wet, to the nostrils in the same way, but use the D'Arsonval current. One terminal of the cabinet is connected to the nasal electrode and the other to the auto-condensation handle and a current carefully turned on as warm as the patient can stand in comfort for five to seven or ten minutes. This is again followed with the sinusoidal current for two or three minutes.

These treatments are given on alternate days to prevent nature from forming resistance to the currents, which she will just as in the case of drugs. If after a time you find you have converted your case from a hypertrophy to one of simple tumefaction, give a few treatments of positive galvanism and contract and tone the fagging blood vessels and again use the litmus paper test and complete the case.

There is one other condition we cannot refrain from mentioning before we close this paper, and that is stenosis, or stricture of the lachrymal duct. This class of cases were a great trial to me when trying to relieve them in former years.

It is no trouble to force a knife or probe through the bony canal, but what assurance have we that the instrument followed the canal? Most often it does not and when healed the case is often worse off than before, as there is more fibrous tissue in the canal. In the negative galvanic current we have our greatest ally in the fight and cure. If the smallest Theobold's or William's probe will pass the stricture you are very fortunate. All necessary now is to select the next larger size, attach to the negative pole, and with the indifferent electrode on the back of the neck turn on the current. You will first test the current on your tongue. Place the indifferent electrode on the back of your neck, having it well covered with a napkin saturated with Sodium

Chloride solution. Then take the probe to which the negative side of your apparatus is attached and lay it on your tongue and slowly turn on the current until you feel a good current passing, then note the position of the needle on the dial of the rheostat. Now attach electric apparatus to your patient in the same manner and insert the probe into the lachromal canthus and sack and mouth of the duct. Turn on the current of same strength as while holding to your tongue and make slight pressure, and in a few seconds the instrument will pass. In three or four days repeat the treatment with the next larger size, and thus continue until you have gone a little farther than normal, which would be about size 10 to 12 probe. Then give two or three treatments of about two minutes of positive galvanic current strength about the same as before. The negative current softens the tissue, while the positive hardens it. This is simply a finishing expedient.

In nervous patients it is well to use a local anesthetic in the lachrymal structures before undertaking the treatment.

When this method is followed the necessity for a cutting operation will be reduced to the minimum.

The uses of electro-therapy in our specialty are legion, and I have only chosen these few classes of maladies as they have been most common or troublesome in my experience, outside of the refractive work, and they illustrate very beautifully what may be accomplished with electricity combined with the other methods known to be of most value.

More About Meckel's Ganglion

By Hiram Byrd, M. D., Ocala, Florida

"I don't understand all I know about this."—Octavius Cohen.

In a previous article I have presented evidence that Meckle's ganglion is at the bottom of glaucoma* and in another that it is no less intimately conected with asthma.** I shall now present a case showing, under control conditions, the formation of a vacuum sinusitis of the maxillary, and how the resulting disturbance is transmitted to Meckle's ganglion, which acts as a broadcasting station from which are distributed the outstanding symptoms of Sluder's syndrome together with others hitherto unobserved or at least not emphasized; and lastly, how such remote conditions as cholecystitis, fatigue and menstruation, through partnership in iniquity, are capable of pulling the trigger that fires off a volley of Meckle's symptoms.

As this article is prepared for both the specialist and the general practitioner, it will be opened with four points of anatomy, to wit: (1) That the maxillary sinus, be it remembered, is a large cavity in the cheek bone; (2) that this cavity has a small drainage and aeration canal which enters the nose in the middle meatus and which is normally open; (3) that hanging down from the external nasal wall over this opening is a flange of bone, the middle turbinate; and (4) that the space between the nasal wall and this flange of bone is ordinarily adequate to permit drainage and aeration but that in some individuals it is very restricted. In such individuals it will be seen that a little turgescence of the nose will block this drainage and aeration canal. It is a case of this kind that will be discussed here with all the consequent symptoms.

The patient has been a subject of headache for a long time—from childhood, in fact. The attacks usually include such symptoms as frontal headache, pain in back of neck, increased tension and soreness of eyeballs, and great prostration, sometimes nausea. Henceforth in this article these will be referred to simply as "headaches," unless otherwise specified.

During such an attack I cocainized Meckle's ganglion when, presto! the symptoms all faded away.

Examination of the nose between attacks showed no pathology but restricted middle meati. That, together with sensitiveness over the cheek during an attack, set me to wondering if it were a maxillary vacuum causing the disturbance and if it could be arrested before it reached the ganglion. When the next attack came on, instead of applying cocaine to Meckle's area it was applied to the middle meatus of the side showing the sensitive check, and as before, the symptoms promptly abated.

While the cocaine was being applied something happened that arrested my attention. A faint little sound was heard like a tiny bubble breaking. It was repeated several times and could be heard something like a yard away. This set me to wondering whether it was the anesthetic or the styptic action of the cocaine that was giving the relief. So the next attack, instead of using cocaine, adrenalin was used. The results were no less spectacular. In subsequent attacks other astringents such as alum, silver nitrate, tannin and chloride of iron have been used. They have all proven effective. Sometimes the relief is quicker than at others—the tissues seem to give a better

reaction. But in all cases relief has promptly followed the bubbling sound.

As I interpret this it is the swelling of the mucous membrane in the middle meatus (sometimes one, sometimes both, as shown by the sensitiveness over the cheek) which closes the maxillary ostium. This closes off the maxillary sinus. This in turn produces a situation analogous to the frontal vacuum described by Sluder and which is capable of setting off a train of symptoms. When the canal is closed the oxygen of the contained air is absorbed, which results in a partial vacuum. Now running through the roof of the maxillary sinus is the infra-orbital nerve, which has direct connection with Meckle's ganglion. The irritation thus set up by the suction force in the sinus has only to be transmitted to the ganglion, there to be broadcasted.

The following is a catalog of the symptoms that I have definitely and repeatedly controlled through Meckle's ganglion—not all in this patient, however. They fall into four groups, namely: *Pain, respiratory disturbances, secretory disturbances* and *motor disturbances.*

Pain.

1. Over cheek bone, both pain and tenderness. Sometimes one, sometimes both.
2. Over eye of same side.
3. In temple, same side.
4. In ear, same side. Not observed in this patient.
5. Behind ear, same side as pain over cheek.
6. At back of head where it joins neck. Perhaps the most common symptom both in this case and others. This important headache is usually classified as "nervous" and treated with aspirin.
7. In shoulders. Fairly common. This is usually passed up as rheumatism. My suspicions are that this has cost many a harmless tooth and tonsil.
8. In arms; also classified as rheumatism. Less common than shoulders.
9. In fingers. More commonly a tingling sensation than actual pain.
10. In chest. A common symptom in the initial stages of a cold characterized by rhinitis. Strictly amenable to Meckle's treatment.
11. In epigastrium. Not observed in this patient, but in another. This patient, however, frequently has nausea.
12. In back. Common.
13. In legs. Fairly common.
14. In eustachian tube—presumably. Description rather vague. Not observed in this patient.
15. In throat. Sense of tightness and of beginning sore throat.
16. In roof of mouth. Sometimes pain, sometimes itching. Not observed in this patient recently but formerly common.
17. In teeth.
18. In eyes. Pain so definitely connected with eyes that patient has been refracted again and again. She is emmetropic.

Respiratory Disturbances.

19. Paroxysmal coughing. Common but mild.
20. Sneezing. Not observed in this case.
21. Asthmatic breathing. Not observed in this case.
22. Sighing respiration. Occasionally observed.
23. Quickened respiration. More common.

Secretory Disturbances.

24. Watering of eyes.
25. Rhinitis. Not common with this patient.
26. Increase of intra-ocular tension. This is interpreted as increased secretion into the eye, which, whenever coupled with poor eye drainage, results in glaucoma.
27. Increase of bronchial secretion following asthmatic attacks. Of course not observed in this case.

Motor Disturbances.

28. Difficulty of swallowing. Not observed in this case.
29. Sense of weakness, general. Very common in this case. Not uncommon in others.
30. In addition to the foregoing I have observed repeatedly in this case, occasionally in others, a sort of eruption over the cheek—a reddish thickened appearance of the skin—during an attack.
31. Also in this case puckering of the forehead is a common symptom during attacks. Not the ordinary puckering of the brow that is under the control of the will, but an involuntary sort of puckering spread evenly over the forehead and extending back into the hair.
32. This patient also began graying in the early teens and now the whole front of her hair is white while the back half is its original brown. There may or may not be a connection.

It is pertinent to add in this conection that probably in no individual are all of these symptoms ever present. Some patients have a single one, some two or three, and some larger groups. The most that I have observed in a single individual is the case in question, some twenty out of a total of about thirty observed. To be sure, she has never had them all at once. The longer an attack lasts the more symptoms are generally drawn into it.

So much for the symptoms that may be broadcasted from Meckle's ganglion. Now as to their causes. We have long recognized "predisposing" causes in a general way but opportunities to see a predisposing cause in action are not common. It is now proposed to show and with what probability of accuracy let the reader decide some of these predisposing causes at work and in various combinations.

To do this one must go somewhat into details of the case in question. She has been a sufferer from paroxysmal headache from childhood. For thirty years or more relief has been sought through all general and special channels that offered hope. Sometimes it has seemed in sight but has always, in the end, proven only partial and only temporary, so that through the years her condition has remained about the same—sometimes a little better, sometimes a little worse.

And though it has never been understood, she has known for years that menstruation, constipation and fatigue have been contributing factors. Four years ago menstruation was subtracted from the complex by the menopause, and two years later cholecystitis reconstructed my notions of the constipation. She had an acute attack which was pretty severe and as soon as she was able to travel went to Atlanta where Dr. Niles put her on non-surgical gall bladder drainage. The results were happy in that the symptoms abated and her general condition improved. Still she continued to have evidence of gall bladder disturbance from time to time and does yet for that matter. But she mastered the technic of the drainage and since that time whenever the gall bladder flares up, drainage soon brings it into subjection.

Since this has been worked out the constipation, which has always been a problem, seems to have melted away and now only puts in its appearance when gall bladder trouble is brewing. I am of the opinion now that she has been a sufferer from chronic gall bladder disturbance for years and that has been the determining factor in the constipation. With the menopause past and with this interpretation of the constipation, the two predisposing causes that she has to watch at the present time are the *gall bladder disturbance* and *fatigue*. Experience has shown that either of these in moderate to severe degree can initiate, singly, a series of events that ends in headache, or the two operating together can do the same, even in mild degree. Each calls for special consideration.

The gall bladder disturbance ranges all the way, in severity, from the point where it is imperceptible to the most severe attack. I have sought, with some degree of success, a method of determining early when an attack is brewing. The earliest symptom to appear and the most uniform in its manifestations is flatus. In the entire absence of flatus she is at her best. She can exert herself to a considerable degree without stirring up trouble. There is no tendency to constipation.

But with the advent of slight flatus, as evidenced by occasional rumblings, her physical activities have to be extremely guarded or they will eventuate in a Meckle's headache.

When the flatus becomes a little more pronounced, so that she is conscious of an abdominal fullness, then Meckle's headaches supervene, whether or no. However, the application of a styptic to the middle meati relieves the headache and other accompanying symptoms till such time as the effects of the styptic have passed, when the headache returns.

In a still higher degree of flatus—that is, when it approaches colic and when there is other evidence of intestinal putrefaction and pain in the vicinity of the gall bladder—then headache is a constant symptom except when under the influence of intranasal styptics. But more than that, the styptics do not relieve the headache entirely. The other accompanying symptoms disappear but the headache itself persists in modified form—less acute, more bearable and absolutely uninfluenced by intranasal applications, even of cocaine. I believe now that this is a different headache from Meckle's—possibly intracranial. The Meckle's comes and goes under the influence of the styptics but this remains till the gall bladder disturbance subsides.

As to the fatigue, a certain explanation is in order. When she is at her best she can hike and exert herself ad libitum with little danger of stirring up a headache. But when the gall bladder is kicking up, ever so slightly, as evidenced by flatus of mild degree, then she has to be more careful. Nor does the fatigue come on entirely gradually as it would seem it should. She may be walking, for example, and feeling at her best, when suddenly she begins to feel exhausted and inside a hundred paces her weakness and exhaustion is such as to make navigation well nigh impossible.

This sudden exhaustion now, I am convinced, is not true fatigue but one of the symptoms broadcasted from Meckle's. The proof of which is that the application of styptics to the middle meati at such times relieves the exhaustion even as it relieved other of Meckle's phenomena.

Here then we have in the lower grades of gall bladder disturbance, recognizable only by mild flatus, a situation that reacts upon the nose so feebly that it must have the addition of fatigue to stir up a headache. Indeed it takes more than that. The nose has to enter into the combination. If the middle meati were large enough to permit the swelling of the mucous membrane without blocking the maxillary ostiae, then no symptoms would result. Or, on the other hand, if the mucous membrane did not swell there would be no symptoms. Both of these features have to be taken into the ring that produces the Meckle's headache.

Just what causes the swelling of the mucous membrane I know not. But her gynecologist (Holden) several years ago advised that she was of low muscle tone. The thought is permitted that it might be *low cell tone*. With low cell tone

it would require only a little additional load to reduce the cells below the functioning line and cell collapse would follow. The toxins resulting from low grade gall bladder disturbance are hardly adequate to do this. With the toxins of fatigue added it is sufficient. Or the toxins of a little higher grade gall bladder disturbance are adequate without the addition of fatigue toxins. In low grade gall bladder disturbance then it seems that there is little room to doubt that four features have to combine to cause a Meckle's eruption, namely: Gall bladder disturbance, plus fatigue, plus restricted middle meati, plus low cell tone.

The case transilluminates five major considerations, namely:

1. The possibility, not to say frequency, of Meckle's symptoms without obvious nasal pathology. The most careful examination of the nose between attacks reveals nothing that could be classed as pathological.

2. That while this case is strictly limited to phenomena growing out of the maxillary sinuses, it is to be remembered that there are other sinuses to be reckoned with, and this suggests the tremendous ramifications of symptoms growing out of the nose as a whole.

3. It also suggests adequate explanation of those cases of asthma of extranasal origin, such, for example, as those arising from intestinal toxemia (Eustis) or intestinal adhesions (Wolf). For we have seen how the intestinal toxemia resulting from gall bladder disturbance has, either singly when severe or in conjunction with fatigue when mild, lighted up the nose again and again. The only reason that this patient is not a confirmed asthmatic like her brother is that headaches and eye distresses, instead of her breathing, have formed the habit of tuning in on Meckle's disturbances.

4. It suggests adequate explanation of glaucoma. In a previous paper evidence has been cited that Meckle's ganglion is the offending nerve in that disease; that through its influence there is an increased secretion into the globe during a Meckle's eruption, and that when this happens to combine with poor eye drainage the result is an increased eye tension. In this case during attacks there is high tension of the eyes, with photophobia and soreness, but the eyes have anatomically good drainage, which is the only thing that keeps her from being a subject of glaucoma. From this it is seen how such remote agencies as toxemia (Bell) may initiate events leading up to glaucoma.

5. The case also offers adequate explanation of the fact that so many women have headache at menstrual time. In her case, as has been seen, headache was an almost constant manifestation at that period, and though these discoveries were not made till after the menopause, there is reason to believe that astringents adequately applied at that time would have relieved her menstrual headaches. Believing this, I have sought opportunity to check it up with suitable cases, of which I have had only two so far, but in both instances have had the satisfaction of seeing menstrual headaches relieved with the intranasal application of silver nitrate.

*Byrd, Hiram: Meckle's Ganglion and Glaucoma, Journal of the Florida Medical Association, August, 1923.

**Byrd, Hiram: Meckle's Ganglion and Asthma, Eye, Ear, Nose and Throat Monthly, Chicago. (In press.)

Iritis Tuberculosa

By J. G. Parsons, M. D., Sioux Falls, S. D.

READ BEFORE THE SIOUX VALLEY EYE AND EAR ACADEMY AT SIOUX CITY, IA., JAN. 23, 1924.

In reviewing the literature on this rather rare condition one is struck with the varying opinions of different writers as to the frequency with which tuberculosis is set down as the cause of iritis. Feber found one case in fifteen investigated—about 7 per cent. Brown and Irons found 8 per cent in 100 cases, while Guttman, in Michel's clinic, found one in 150 cases. Pockley, in a paper published in 1920, thinks that 8 per cent is "beyond the limit."

The condition is described by different authors in brief as follows:

Fox: Pale yellow nodules some distance from the edge of the iris in the lower half. Associated with tubercular changes in adjacent lymph glands, usually attacks young tubercular patients. "No symptoms of acute inflammation." May be confluent, with tendency to spread, causing rapid destruction of the eye.

May: Rare. Affects children and young adults. Nodules near pupillary or ciliary border. Conglomerate at ciliary border.

Sydney Stephenson: Solitary granuloma. Patients usually under 20, often having other signs of tuberculosis, especially of glands, bone and joints. Differentiated from syphilitic condyloma by history and other signs. From sarcoma, which is vascular and progressive. From ophthalmia nodosa due to caterpillar hairs, also involving sclera and conjunctiva. From lepra by history and usual involvement of cornea and conjunctiva first.

De Schweinitz: Occurs usually in patients under 25. Nodules at margin of iris or at ciliary border, having appearance of miliary tubercles. May develop slowly and be absorbed. Successive developments may lead to plastic iritis and cyclitis. Keratitis punctata develops. Liable to increase and perforate at cornea-scleral junction. Confluent form may occur at periphery; covered, it may be, with smaller bodies. Usually increases in size, perforates and causes general tuberculosis.

In the literature reviewed by Gamble and Brown in 1905 references are made to the use of tuberculin for diagnostic and therapeutic purposes in interstitial keratitis, phlyctenulosis, dacyocystitis, iritis, tarsal excrescences, corneal ulcer and conjunctivitis.

While no specific reference is found in this review as to the co-existence of iritis with any of the above named conditions, doubtless there were occurrences of this kind.

I have under observation two cases which developed iritis in the course of phlyctenulosis and interstitial keratitis, which were arrested under tuberculin treatment, one remaining free from any recrudescence for over ten years, and the other recently lighting up after a quiet period of about five years.

A third case which I wish to report in particular is of unusual interest because of the history, age of the patient, associated lesions, diagnosis and response to tuberculin treatment.

Mrs. V., age 52, referred June 3, 1922, with diagnosis of frontal sinus involvement. History: Had severe attack pain in region left eye 25 years ago. Intense pain suddenly relieved after profuse gush of pus from nose. Subject to frequent colds and sore throats. Had frequent attacks of sore eyes in childhood, requiring confinement in dark room. Vision very poor in left eye.

Status praesens: One week ago had sore throat, with severe headache. Left eye became swollen at upper inner angle and above eye. Eye red and painful to touch. General headache very severe on stooping. Pain worst in occiput.

Slight discharge of thick yellow pus from left nostril.

Examination: Very tender left frontal floor and left canine fossa.

Nasal examination: Swollen middle turbinal in contact with septum on left side. Pus oozing from beneath turbinal, which did not shrink with cocain and adrenalin. X-ray shows distinct shadow of left frontal sinus and antrum.

Left eye tender to touch, pericorneal injection, photophobia. Pupil shows synechiae, causing irregular dilatation under atropin. Vision not taken but evidently greatly diminished. Examination of fundi shows nothing especially abnormal in right eye, which also had synechiae, but no satisfactory picture could be obtained in the left, due to haziness.

Diagnosis: Acute frontal and maxillary sinusitis, with iritis of left eye.

Treatment: Atropin and salicylates. Topical application of adrenalin and ichthyol-glycerin to middle turbinal. Failure to secure relief of frontal symptoms led to intranasal drainage of the sinuses two days later. Relief of pain followed, although the iritis persisted for some time.

Oct. 19, 1922, patient returned. Had been comfortable all summer until one week previously when pain in face and temple returned. Nasal examination showed that the antral opening had closed. This was re-opened with rasp and forceps. Theatments were continued two or three times weekly, including sounding the frontal. The frontal pain continued to be severe, so a radical frontal drainage was instituted Nov. 2, 1922. The sinus cavity was found filled with polypoid granulations which were thought to explain the failure to get the desired results. An uneventful recovery ensued, leaving a beautiful cosmetic result. The patient remained comfortable but returned on Jan. 10, 1923, for relief from a dacryocystitis of both sides. The ducts were easily probed and irrigated with 1/5000 mercuric cyanide. These probings were carried out twice a week.

On Jan. 26, 1923, she complained of pains in the eye and examination showed what I took to be an exudate similar to a hypopyon in the anterior chamber. This had developed within the past three or four days, as it could hardly have been overlooked while probing the tear duct. Two days later it was possible to make out a distinct mass which was not hypopyon.

On Jan. 31 Dr. Gregg saw her with me in consultation. At that time it was possible to make out a distinct granuloma, having a base about 5 mm. broad and extending upward toward the pupil about 2½ mm. Vessels running over the surface were distinctly visible.

The eye had been kept under atropin. The fundus was more hazy and vision markedly reduced.

In attempting to make a diagnosis we were considering three possibilities: Syphilis, tuberculosis and sarcoma.

Syphilis was excluded on history; negative Wassermann and negative results with KI. Von Pirquet was negative and there had been no history pointing especially to tuberculosis. The patient had been a vigorous woman who had taught school for many years, complaining only of the severe headaches and attacks of iritis. She had never had any previous epiphora, by the way.

The rapid development of the growth was very suggestive of sarcoma. Injections of old tuberculin were begun, increasing from 1/1000 mg. up to 1/100 mg. on Feb. 14, when a local and focal

reaction were obtained. This treatment was continued, with a slight improvement until the latter part of March, when, learning that she planned to visit relatives near Omaha, I advised her to consult Dr. Gifford who saw her on April 6.

Dr. Gifford in his letter stated that while he should not like to say whether the tumor was sarcoma or tuberculoma, the form of iritis would indicate that tuberculin was the proper treatment.

She returned after the absence of a month, without the tuberculin, showing a steamy cornea, with numerous punctate spots about 1 mm. in diameter. No retinal reflex to be seen. The vision was reduced to light perception. The growth had not increased in size. The dacryocystitis was quite troublesome, pus being expressed from both sacs. There was also a fungoid growth about 2 mm. in diameter hanging from the middle of the upper lid margin. This was excised. Section showed granulation tissue. She was now content to try to fight it out with tuberculin treatment. The dose was gradually increased, rapidly working up to a dosage of about 7 mg. This was continued twice a week until Dec. 1, since which time the intervals of treatment have been reduced to once in two weeks.

At the time of this writing Jan. 1, 1924, the patient's condition is as follows: No dacryocystitis for last four months. Since Dec. 1 growth has been reduced to a mere scar line at the ciliary margin. The site of the growth on the iris is marked by some atrophic streaks. Vision 12/200. Cornea entirely clear. No satisfactory view of fundus obtained. Patient has occasional neuralgic pain along distribution of supraorbital nerve. No discharge from nose. Mucosa appears normal. The following points are of especial interest:

1. The age of the patient. Most cases reported are in young adults or children. This would throw suspicion in the direction of sarcoma in making the diagnosis.

2. The history. Several attacks of iritis covering a period of over 25 years. However, the definite tubercular element has not appeared before, suggesting that we have here a tubercular infection engrafted upon an old plastic iritis.

3. The associated lesions. The response of the dacryocystitis to the tuberculin indicates that this infection was of tubercular origin. There is a possibility of a tubercular element in the frontal sinus lesion. This may well suggest that tuberculosis be considered in cases of chronic sinusitis.

4. The diagnosis. The rapid development of the growth was decidedly suggestive of malignancy, especially when considered with the age of the patient. The value of tuberculin in establishing the diagnosis is to be noted.

5. Tuberculin treatment. The result obtained is remarkable. The size of the dose which was tolerated was considerably larger than usual.

MAR 8 1932
DIVISION 48

Suction Tonsillectomy

By J. E. Braunstein, M. D., Brooklyn, N. Y.

The surgeon's aim in all surgical procedures should be to attain the best end results in the interests of the patient and the method employed is important only, when the technique, leads to that end. After all, it is the end results, in which we must be interested. If we can say to the internists, who so severely criticize the nose and throat surgeons because of resulting complications following tonsillectomy that we are doing everything possible to curtail bad results, the instrument which I present for your consideration tonight deserves your attention.

We must therefore not be too critical with anything new until it has been given a fair trial contributing our patience to fine and exacting details, and then condemning it if it is not found worthy. Many surgeons have said to me, "I have performed numerous tonsillectomies and never have I encountered a lung abscess as a sequelae. I may have been just as fortunate and can only answer in agreement with the report of Coakley and Pratt, as it appeared in the "Laryngoscope" of Feb., 1922, which reads as follows: "We have had one case of lung abscess following tonsillectomy. T. A. S., fifty years, had been subject to attacks of tonsillitis before coming under our care. He suffered from diphtheria in March, 1919; acute tonsillitis in May, 1920. Tonsillectomy was advised and performed under local anaesthesia June 11, 1920. Operation was performed in the upright position and less than a dram of blood was lost from the two tonsils combined. Immediately after the operation patient was placed in a wheel chair, taken to his room in the hospital and put to bed, given a hypodermic injection of ¼ grain of morphine sulph. to relieve the pain. Thirty-six hours after the operation, in the middle of the night, he complained of severe pain in the right side. He had been subject to so-called rheumatic pains and his case was diagnosed by the house surgeon as intercostal neuralgia. A thorough physical examination was made the next morning by a very competent internist, who concurred in the diagnosis and

606/115

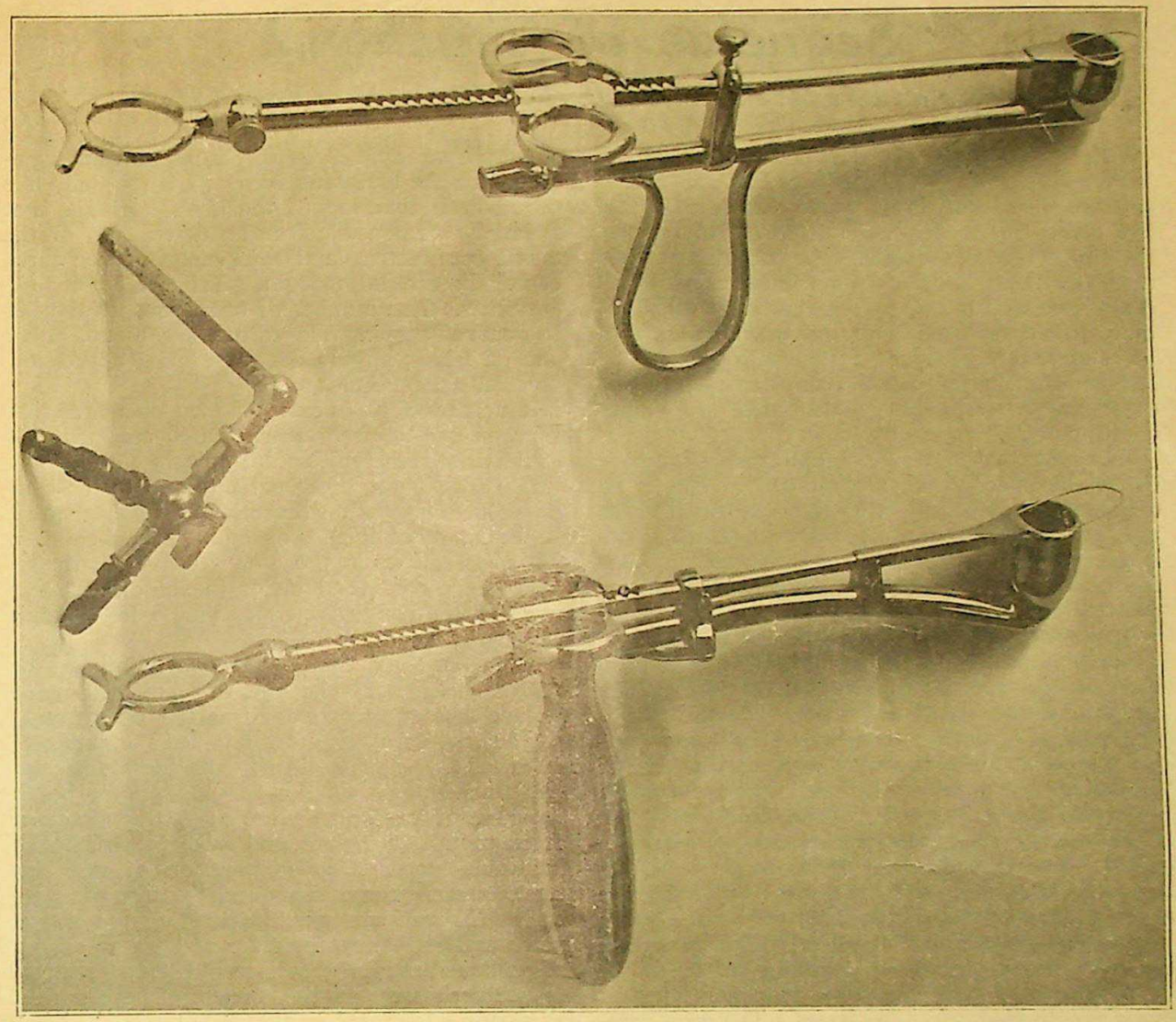

is broad and covers about two-thirds of the tonsil, when there are adhesions as a result of a previous effort to remove the tonsil, a schirous tonsil, when cartilage exists in and about the cleavage point between the tonsil and the tonsillar bed, and if for an unforeseen reason the depth from the mouth of the instrument is too large or too small.

Having in mind the anatomical relations of the tonsil, the mouth of the snaretome or metal tube is applied directly over the tonsil and to obviate too many sizes, large tonsils may be massaged into the opening and then allow the suction to grasp it. The smooth edge of the snaretome avoids the pillar, soft palate, and only when the plica triangularis is broad, or adhesions exist, it may be necessary either to elevate or cut through for it acts as a barrier against suction, on account of being in a taut condition. With this eliminated, the suction tube grasps the tonsil into its mouth and receives the tonsil and capsule only because it is loosely connected by areolar tissue which separates it from the aponeurosis and fascia lining the superior constrictor muscle and nothing else can enter and a dimple is noticed which is to indicate the tonsil is within the tube. The snare is then closed. The tonsil is thus completely enucleated and remains in the tube with all of its contents. We then observe that the fossae are completely lined by the aponeurosis, bleeding points if any are visible. The pillars are complete. No tonsillar contents is expressed into the pharynx.

The number of instruments are very few, just a snaretome, mouth gag, tongue depressor, and suction apparatus, and sometimes a knife.

In order not to lose the valuable aid of the Yankauer suction tube, I have a two way pet cock connection having nozzles to which suitable suction tubing is attached connecting same with the "Yankauer and Suction Snaretome."

Sequelae of Trachoma

By Sanders M. Payne, M .D., F. A. C. S., New York City

As a result of the above conditions the cul-de-sac is obliterated: the conjunctiva descends directly from the eyeball to the tarsi. These sagoseed-like bodies are located in the retrotarsal folds in the connective tissue cells. As the inflammation increases these bodies become larger and break down into a soft mass. At this stage they are more easily removed with the trachoma forceps but better to be removed earlier as it may be too late to save the cul-de-sac from damage and the extension of the bodies to the tarsal and ocular conjunction.

Our text books advise an application of a caustic to the bodies such as sulphate of copper or nitrate of silver or any other mild caustic. Though the favorite is bluestone, if this was applied strictly according to directions—that is, gently touch the bodies where they are mainly in the cul-de-sac—cure may be accomplished before the tarsal conjunctiva becomes involved severely.

My observations as a student and after I began work in two eye clinics was that the direction in applying the blue stick was lost, but instead, automatically swiping the stick across the tarsal conjunctiva and a second stroke between the edge of the turned tarsi and the eyeball, not far enough to reach the cul-de-sac. This bluestone stick swiped across the tarsi every second day when the tarsal conjunctiva was hardly involved or slightly so, not only increased the inflammation of the conjunctiva but the tarsi also, automatically neglecting the primary location. This was due more to the hurried way of running off the clinic.

In this automatic bluestone treatment the results are divided into two classes. The most common of the two is the entire loss of the tarsal conjunctiva. This does not stop the bluestone treatment, which may be continued on for a dozen years or more. How much the trachoma is responsible for this cupping of the tarsi is hard to say, but the continued bluestone treatment will destroy more of the conjunctiva which increases the cicatritial contraction with an increase of the entropian and with increased rasping of the cornea. The other class which has been under the same treatment is of a different form. The retrotarsal folds and palpibral conjunctiva are highly inflamed and swollen. Before the destruction of the tarsal conjunctiva a thick granulation or proud flesh which is increased by the bluestone increases the rapidity of the lid movement scratching the eyeballs by every sweep of the upper lids and aggravating the already congested vessels coming from the lids and eyeballs. We may have pannus without the bluestone treatment but not so severe or rapid in its formation as when reinforced by the bluestone stick. It is this jelly-like proud flesh covering of the tarsal cartilage that is largely responsible for the destruction of the tarsal conjunctiva and thickening of the tarsi, especially the lid margin. *Trichiciasis or districhiasis.* The number of operations on the lids to prevent rasping the cornea are many, either one of which largely destroys facial expression, especially a cantholocis.

Trachoma forceps came into use about the time I began eye work in 1886 though confined only to the new cases which were quickly cured. This was a blessing to these patients and to the community at large as a preventive of further spread in the family or friends or among school children. My observations in those days were that the old cases were continued under the bluestone treatment on the assumption that they were not suitable cases for the forceps.

I had watched those bluestone treatments before I had joined the clinics. This led me to believe that the treatment was too severe and I decided not to use it after I joined the clinics. I observed these same old patients for many years and noticed that what was supposed to be the sequalae of trachoma were gradually increasing from month to month and year to year to the incurable stage. My observation of the bluestone treatment was that directly after the application the patients would return to the waiting room and shed blue tears for at least an average of an hour before the eyes would clear up enough to see their way on the streets. These patients as a rule were loyal to the doctor who had been treating them and preferred no change of doctors, so the staff each had their old patients provided they were at the clinic. When one of these old patients came under my charge I would cocainize the eyes, give the upper lid a double turn with the Noyes forceps, thus exposing the cul-de-sac and express the remaining bodies out with the Prince forceps. If the bodies were broken down into a mushy mass, involving the entire mucosa, I would follow up the forceps with a thorough rubbing with 1 to 500 solution of bichloride of mercury on a cotton applicator. These patients during this process would make demonstrations that would cause the others to be nervous, but when the torture was over they would walk out on the street with their eyes wide open.

As these patients belong to the bluestone regiment they were closely watched as they walked past their comrades to the street. Two days later the improvement was so noticeable that one of

the comrades would request the orderly to have me treat them. Each clinic would give me a new convert. As they were cured so quickly they were not there to count noses with others who had to continue indefinitely. If they could have been called back on a specified day I believe they would have out-numbered those remaining under the old treatment.

In either of the two conditions when the cul-de-sac tarsal cartilage and the ocular conjunctiva are cured we may find the vision still poor. We either find remains of Pannus or the vessels extending from the lower lids upward on the cornea or vessels from all directions; when left alone they remain indefinitely. This condition I coined the word chronic vascular keratitis. They may be divided into two classes. One has the appearance of central opacity of the cornea, and when they come from another clinic in that condition they are put down as corneal opacity by the casual observer, because there seems to be no vessels approaching the central group. In the other class the vessels can be seen crossing the corneal margin and bifurcate in all directions like the limbs of a tree. The first group I have cleared away entirely by the tattoo needles at one or more sittings. The other I have destroyed every vessel with the platinum cautery held over an alcohol lamp by touching the large vessel back of the bifurcate on the schlera. All the branches from the larger vessels are destroyed. Only once I cauterized two vessels at one sitting. As the reaction was considerable, I confined my operation to one vessel at each sitting. I shall report one case of each so the results may be more highly appreciated.

I shall mention Miss J. W. who was under the bluestone treatment for eight years at the old Manhattan Eye and Ear Hospital, 41st street and Park avenue. After she had been treated five years one eye was enucleated, and after the other eye had been treated three years longer, Dr. W. said: "Julia, I am afraid you are going to lose that eye as you did the other. Come to my office so I can treat you every day and see if I can save it." As I was working in his office at the time I was able to see that there had been no change in the treatment and could see that with the daily treatment she was losing the sight faster and that she would certainly lose her eye unless the treatment was changed. I ventured to suggest that he do an expression. He refused to take my suggestion by saying that there are no trachoma bodies to express. I said they are covered up by proud flesh. He said they have gone long ago. A few days longer she had to be led to the office by her mother. I felt sure that the eye could be saved if he would take my suggestion and use the forceps. Watching her vision daily going kept me awake at night worrying over her last hope for vision. The doctor also said he could not sleep for worrying over the case. It was all the harder for me because professional courtesy prevented further interference. When the vision was reduced to fingers at 10 or 12 inches the doctor in the presence of the mother said to me: "Julia is going to lose her eye. I have used everything I could think of; as she is going to lose it anyway, I am willing to try your suggestion" With no reply from me I dropped in a 4 per cent solution of cocaine and sterilized the Prince forceps. When I handed to him the forceps he refused to take them and said: "I will never do anything I have no faith in. You suggested it. You must do it because she is going to lose her eye anyway." In the expression the broken down mass of trachoma bodies came out along with the proud flesh. When she came the next day her vision was 15/200. As the lids got better I was able to see if any bodies remained to be expressed.

The bichloride of mercury, 1 to 500 solution, was freely rubbed into the cul-de-sac and on the lids where the granulations were partly caused by the bluestone. The vision became stationary at 20/50. In previous cases where the smaller vessels would not disappear from the cornea I gave them a name which I had not seen in the text book—chronic vascular keratitis. As these fine blood vessels spread over the cornea which were branches from the larger vessels just off the cornea near the limbus, I conceived the idea that to touch the large or main vessel near the cornea with a platinum applicator held over a flame from an alcohol lamp would destroy these small vessels. I mapped out these small vessels with a strong lens and only one vessel was cauterized at each visit. In this way every vessel disappeared from the cornea. The final result was vision 20/15 and accepted plus 1 D. which was prescribed for both eyes. This patient got married and raised a family.

Another of the old bluestone regiment cases was Miss L., age about 16, a patient of Dr. G., who did a tenotomy for convergent squint; later tenotomy on the fellow eye, with no effect; then a tenotomy again on the squinting eye which caused this eye to have a decided divergence. He then treated her for trachoma for two years before she requested the orderly to have me treat her. When I had cured her trachoma by the same method that I had the others, she requested me to straighten her eye, which I did with my method as follows: Single thread with a needle on each end of the thread. I then cut the muscle from its false attachment, passed one needle into the schlera and out at the original muscle attachment, then grasped the end of the muscle with fixation forceps, passed one needle through the end of the muscle on each side of the forceps, bringing the

muscle up with the forceps, taking up the slack thread with it until the thread was held vertically over the entrance and exit of the threads in the schlera, then tied the thread across. This fixes the muscle so it cannot slip back, which insured binocular single vision.

This patient was one of twenty girls employed in tying ribbons around fine box paper. She appealed to me to do something to improve the looks of that eye (central opacity) so she would not be discharged. She said the other girls had told the proprietor that they would go on strike if she was not discharged as they were tired of looking at her bad eye. The proprietor said he would have to ask her to leave unless she had the eye fixed; that he could not lose the others on her account. I tattooed this opacity which was directly over the pupil. My aim was to tattoo with the India ink so it would stay a long time. I did the tattooing so thoroughly that it remained much longer than usual. While this eye was being tattooed I noticed some blood which I judged was from the end of vessels reaching to the center of this opacity. When the India ink had all disappeared the cornea was clear. This experience led me on to further investigations. After this every old corneal opacity case I could find in the clinic I would take in the dark room and use the direct method with a strong plus lens of my ophthalmoscope. With this opacity between the lens and the pupil and red reflex from the retina would show that this supposed scar was a network of blood vessels. When tattooed with or without the India ink the vessels would disappear with restored vision. Some of these cases were really scar tissue but the majority were blood vessels. Most of these cases had visited the clinics for months and were marked on the card opacity of the cornea.

As the bluestone treatment seems to be universal, the criticism is meant for all who use it. This automatic way is probably due to the hurried way in getting through with a large clinic. When our greatest authors in Europe and America recommend caustic application for trachoma, all give as their preference the bluestone stick. The eye surgeons and assistant surgeons blindly follow without one thought of condemnation or of abandoning it for some other method of treatment.

I will mention another interesting case. J. L., an Italian who was treated in one of the clinics in the Manhattan Eye, Ear and Throat Hospital, who became discouraged and went back to his native country and was treated in Rome for a year. He again became discouraged and returned to the Manhattan. As he had to be entered as a new patient and I on that day was reviewing the new patients, he came under my charge and cured. Several years later he met me on the street and said that he owed his happiness to me for curing his eyes which enabled him to marry the girl who had waited for him for eight years and now we have a dear little baby girl. He said when he had lost hope of ever getting his eyes in a condition to be able to support a wife and requested that she look for another who would be able to provide for her, she said she could not care for any one else and that she would wait for him patiently in the hope that he would finally find someone that would cure him. I mention these cases to show that when we are not getting results we should not continue the same treatment for years with little if any useful improvement, the patient losing three afternoons a week from work, besides handicapped when at work, perhaps not able to earn a decent living for self and dependents. We should think of these clinic patients more seriously, and their dependents, and try other ways that may cure them instead of using the same treatment so long that we cannot get away from it.

FOOTNOTE.

The subscribers to the Eye, Ear, Nose and Throat Monthly will please notice in my paper in the February number on the "Action of the Eye Muscles" that a mistake was made in not having all my ophthalmoscopic and test lens findings marked plus. In the hundred and one cases there are thirty mistakes. Mark them plus. The mistakes by number are: Cases Nos. 20, 28, 41, 42, 43, 44, 45, 46, 47, 48, 49, 51, 52, 55, 56, 57, 58, 59, 61, 67, 68, 75, 78, 79, 80, 90, 94, 95, 98, 99.

The paper deals entirely with hypermetropic eyes. The left hand column shows astigmatic *old glasses,* either minus or plus.—S. M. Payne.

A Post Graduate Course at Bordeaux, France

Arrangements are being made for a five weeks' intensive post-graduate course in broncho-oesophagoscopy and in plastic and mastoid surgery by Professors E. J. Moure and Georges Portman of Bordeaux University, to be given in Bordeaux, France, from June 8 to July 15, 1924. The lectures will be given in English and the course will be complete in every scientific detail.

Professors Moure and Portman are both of them well-known and distinguished leaders in oto-laryngology and it will be well worth a man's while to make a trip to Europe next summer for the sake of taking advantage of this excellent post-graduate work. The class will be limited to thirty students, so that those who intend to take it in will do well to enroll at once. For detailed information apply to Dr. Leon Felderman, M. D. 4428 York Road, Philadelphia, Pa., who has charge of the arrangements.

The Problem of the Stammering Child

By Abraham R. Hollender, M. D., Chicago, Ill.

The old belief that a child will "grow out" of stammering is no longer held to be sound. On the contrary, the impediment grows progressively worse, and as the child passes into adult life, the problem presents greater obstacles in the way of permanent relief. Recently, the child with defective speech has commanded much attention from his parents, teacher and physician. The agitation of certain individuals and organizations exclusively interested in speech disturbances is responsible for this. As a consequence the parent who attributed stammering to obstinacy or carelessness, the teacher who lacked patience and sympathy, and the physician who failed to volunteer proper co-operation, are now a unit in fostering the systematic correction of stammering in the child.

Often this disturbance may be traced from some difficulty at birth. In later infancy, the acute contagious and infectious diseases, particularly the scrofulous conditions and rickets predispose. From the neurologic side, the child may show a nervous excitability, termed by some a "psychoneurosis." Imitation, intentional or unintentional, is a frequent factor in the production of stammering, which results from the association of a normal child with a deaf mute.

Statistics show that 2 per cent or more of all school children have some speech disturbance. Heretofore no classification of the various types of defects was attempted. But now, the school teacher, and even the parent, is able to determine the particular type with which a child is afflicted. With reference to stammering much diversity of opinion exists as to what it is. It is not infrequent for the term "stammering" to be applied to a case of stuttering. And some writers would eliminate "stammering" because it is used as identical with "stuttering" and causes much confusion in discussing the two conditions. Scikorski has shown stammering to be a sudden disturbance of the continuity of articulation caused by a spasm which, in a part of the speech apparatus, appears as a physiologic entity. The fact remains that stammering is practically always an individual phenomenon—no two cases presenting the same symptoms. This is because one child may have some physical impediment, another, some neurologic predisposing factor, and still another no apparent cause, but habit or a combination of any two or all.

In the past decade, investigators interested in speech disorders have come more and more to recognize the influence of physical impediments. In the schools there is always a segregated group of children called the "subnormal class." Many of these children range in age from eight to sixteen years, and possess the mentality of normal children many years younger. A considerable number of these "backward children" are so, chiefly on account of a slight physical imperfection of some part of the organs of speech. And it is in the correction of the physical imperfection that the first step is taken toward the uplifting of the "backward child." Some so-called curers of stammering believe there is nothing the matter with these children physically, that their difficulty is entirely elocutionary. In retort to this contention is the statement of a worker of much experience who writes, "On the contrary, there are very few cases of stammering indeed in which there is no necessity for medical aid before elocutionary."

The foregoing statement is of no great significance except to emphasize that the medical side of this speech problem is finally gaining greater and greater recognition. In speaking of the physical impediments one must take cognizance of the report of J. S. Greene, who, in the Medical Record of July 2, 1921, gives a survey of the various mouth and jaw conditions responsible for defects in speech. According to this writer dentistry plays an important part in speech. The tongue also has always been considered a valuable and important instrument for normal speech, yet it has been shown that defects of the tongue often produce only minor defects of speech. The roof of the mouth has a great acoustic influence upon the tone of the voice and the quality of speech, while the arch and height of the palate has much to do with the development of the nasopharynx.

C. G. Stivers, in 1922, made a survey of 1,044 cases admitted to the Orthopedic Hospital School of Los Angeles, from 1918 to 1921, and found that 7½ per cent had, along with their orthopedic trouble, some form of speech defect. Stivers is of the opinion that there are from five to ten times as many speech defect cases among the handicapped as there are in a similar number of other children of school age. "The faculty of speech is one of muscular co-ordinations, and when the power to co-operate the various parts of the speech function, that is, of ideation, respiration, phonation and articulation, is lost, language production will be absent or imperfect. The crippled, the spastic, the inco-ordinated child, cannot form habits of response to objects, and the language development may be hampered, delayed or unde-

veloped, because of the physical handicap."

The study of Smiley Blanton illustrates interesting phases. His report was published in the Journal of the American Medical Association in 1921 under the title "The Medical Significance of the Disorders of Speech." Blanton calls attention to an often overlooked cause of speech disorders. "Severe oral inactivity and faulty construction, particularly of the final consonant sounds, have been classed as an endocrine—vitamin disorder group. The factors that stand out most clearly are (1) a marked similarity of the speech system; (2) uniform vitamin deficiencies of water soluble B., and (3) a history, in a large percentage of the cases, of disthyroid condition in the mother, and (4) history of marked food disorders in infancy."

"Another factor is hereditary tendency; there seems to be a marked predisposition in families of these individuals toward defects of speech, not only stuttering but other defects. There is very little relationship between poor health and the severity of the stuttering, but there is an exact correlation between social adaptation and the severity of the symptom."

Of the mechanical obstructions to speech development, one needs only mention such pathology as diseased tonsils and hyperthrophied adenoids. Next in importance are intra-nasal obstructions, because these interfere with the development of the respiratory system. As one writer has put it, stammering may be a neurosis in many instances, and its origin may be due to a reflex disturbance coming from pressure within the nose.

While the tendency in reviewing the various possible causes of speech development is to cover all neurologic and physical factors, the one cause which is commonly not considered is deafness. Hudson-Makuen called attention to this obstruction in 1911 in a communication published in the Laryngoscope. With deafness, either complete or partial, is a certain mental deficiency which the child possesses, and such a child "cannot speak accurately or connectedly because he has no well defined ideas with which to conduct the mental operations necessary to the formation of the resulting ideas."

Thus the child who stutters or stammers or speaks defectively at all is indeed a problem. The parent, the teacher and the physician all have their work in seeking to bring about some sort of relief or a "cure" if such is likely. The specialists, the otolaryngologist and the neurologist—the greatest problem of all is theirs. They must determine the etiology of the disorder, and cooperatively with the parent or guardian, aim at the correction of all physical obstructions. Besides these, they must carry out a program of re-education best suited for the individual case.

30 North Michigan Avenue.

Carcinoma of Lingual Thyroid

According to Dr. Albert F. Tyler, in the *Journal of Radiology*, of the Department of Roentgenology, John A. Creighton Medical College, Omaha, who reports an illustrative case, the term "lingual thyroid" is applied to a tumor in the root of the tongue due to failure of the thyroid to migrate to its normal position during embryonic development. The condition was first described in 1853 by Vernueil, who discovered it in dissection of the insertion of the muscles of the tongue to the hyoid bone. The first case reported in American literature was that by Bernays in 1888. In 1922 Heartley collected 44 cases, including one of his own. The condition is found at all ages. In Hickman's case the tumor was of sufficient size to produce suffocation in a new-born child, while Staelin's patient was a woman, aged 77. Although present from the first month of intra-uterine life lingual thyroids seldom produce symptoms before the period of sexual activity, so that they are usually recognized between the ages of 15 and 40. Of the 45 cases now on record, 41 were in females and only four in males. The tumor is usually situated above the hyoid bone in the posterior portion of the tongue at the site of the V-shaped groove. It most frequently occupies a lateral position, though occasionally, as in Bernays' case, it is located centrally surrounding the foramen cæcum. It is usually ovoid in shape, and varies in size from 0.5 to 5 cm. in diameter. The mass usually produces a prominence on the dorsum of the tongue, and when it has reached a certain size projects downwards beneath the mandible and above the hyoid bone. The principal symptom is a feeling of pressure in the throat, causing dysphagia or dyspnœa. A desire to "clear the throat" is usually present for several years before the cause is recognized. Occasionally profuse hemorrhage occurs from rupture of one or more of the enlarged vessels in the growth. Lingual thyroid must be differentiated from other tumors which occur at the base of the tongue, such as sarcoma, lipoma, angioma, gumma, and lingual tonsil and cyst. Medical treatment in the form of administration of sodium iodide or other drugs has little or no effect. The use of the galvano-cautery should be avoided owing to its inability to remove all the thyroid tissue. Surgical enucleation by the intra or extra-oral route is the best treatment. The use of X-rays is beneficial in cases where removal is impossible or malignant degeneration has taken place. Dr. Tyler's case, which occurred in a man aged 54, was remarkable for the fact that the tumor which had first been noticed eight years previously had undergone malignant degeneration and was complicated by metastases in the lungs. Complete removal was impossible, but X-rays and radium caused considerable relief.

The
EYE, EAR, NOSE & THROAT
MONTHLY

EDITORIALS • ABSTRACTS • • • REPORTS • • PERSONALS

EDITOR
THOMAS G. ATKINSON, M. D.

ASSOCIATE EDITORS

DR. D. T. ATKINSON, San Antonio, Tex.
DR. HARRY BOYD-SNEE, South Bend, Ind.
DR. AUSTIN F. BURDICK, Lansing, Mich.
DR. DON M. CAMPBELL, Detroit, Mich.
DR. T. ALEXANDER DAVIES, Toronto, Ont.
DR. JAMES C. DOWLING, Washington, D. C.
DR. LINN EMERSON, Orange, N. J.
DR. FAYETTE C. EWING, Alexandria, La.
DR. THOMAS FAITH, Chicago, Ill.
DR. THOMAS J. GALLAHER, Denver, Colo.
DR. HERBERT M. GODDARD, Philadelphia, Pa.
DR. BURTON HASELTINE, Chicago, Ill.
DR. HAROLD M. HAYS, New York, N. Y.
DR. JOSEPH D. HEITGER, Louisville, Ky.
DR. HERMAN JARECKY, New York, N. Y.
DR. ELMER L. KENYON, Chicago, Ill.
DR. GEO. H. KRESS, Los Angeles, Cal.
DR. PARK LEWIS, Buffalo, N. Y.
DR. HUGH M. LOKEY, Atlanta, Ga.
DR. GEO. W. MACKENZIE, Philadelphia, Pa.
DR. OLIVER McDIARMID, Brandon, Man.
DR. EDWIN McGINNIS, Chicago, Ill.
DR. CLIFTON M. MILLER, Richmond, Va.
DR. DEAN W. MYERS, Ann Arbor, Mich.
DR. FRANK J. NOVAK, Jr., Chicago, Ill.
DR. T. E. OERTEL, Augusta, Ga.
DR. SELDEN SPENCER, St. Louis, Mo.
DR. FRED STAUFFER, Salt Lake City, Utah
DR. EUGENE S. STROUT, Minneapolis, Minn.
Dr. JOS. A. STUCKY, Lexington, Ky.
DR. OSCAR WILKINSON, Washington, D. C.
DR. NORTON L. WILSON, Elizabeth, N. J.

Original manuscripts and scientific contributions should be addressed to the editor, and submitted to this journal exclusively.

Proofs of original articles are, unless otherwise ordered, furnished to authors in galley form, which should be corrected and returned promptly.

Reprints, if desired, should be requested at the time of submitting the manuscript, so as to insure the saving of the type and the prompt delivery of the reprints.

Illustrations, if any, should accompany the manuscript. The Monthly is glad to undertake the making of suitable cuts, halftones, microphotographs, as needed to illustrate the article.

Copyright for all original matter appearing in the Monthly remains, unless otherwise arranged, with the journal.

Books for review should be sent to the editor. They will be reviewed as early as possible after receipt.

News items and reports of the proceedings of societies are earnestly invited from all parts of the field. As it is of the highest importance that events be reported promptly after their occurrence, such items and reports should be transmitted to the journal early.

The forms go to press on or about the tenth of each month. Advertising copy and items for prompt publication, therefore, should reach the office of the Monthly not later than the first.

Eyes and No Eyes

It is unfortunate that ophthalmology, in its effort to relieve the ills and better the condition of mankind, should have to suffer misrepresentation and hindrance at the hands of the profession; and especially from those who occupy places of public office and authority. It is bad enough that the laity should, of itself, misunderstand our aims and our work without being instigated thereto by those who ought to know better and to teach more truly. To all of which remarks we are impelled by the reading of a bulletin recently issued by Dr. Herman N. Bundesen, Health Commissioner of the City of Chicago. In this bulletin the Commissioner makes a plea for "the co-operation of all good citizens in an effort to forestall the gloomy prophecy of an English scientist who recently visited this country that within a hundred years every man, woman and child in the United States will be wearing glasses."

We pass over the unscientific foolishness of the English "scientist's" prophecy and would be glad to know just what measures it is proposed to take to reduce the wearing of glasses. People do not, with rare exceptions, wear glasses because of diseases of the eye, but because of errors of focus, due to the shape and size of the eyeball. So far as we are aware nobody has any definite knowledge of how these conditions of the eyeball come about or how to prevent them. For the present, at all events, they must be regarded as simple biologic inequalities in development, in the same class with long arms and short legs. They cannot even be considered as "freaks," since the majority of individuals have them.

This, however, is not the most serious aspect of the incident. The truth about the situation is exactly opposed to the alarmism of Dr. Bundesen and his English "scientist." The present-day accuracy in correcting errors of refraction and the widespread practice of wearing glasses—to which ophthalmologists have with great difficulty and perseverance at last succeeded in persuading the public—constitute one of the most potent factors in the conservation of human health and the increase of human efficiency, to say nothing of comfort and convenience. If anything be still needed, it is more, not less, wearing of properly fitted glasses, for there are still many people not wearing glasses who ought to be wearing them for their own welfare.

All of these considerations were courteously brought to the attention of Dr. Bundesen by the editor of this journal, but up to the present moment we regret we are unable to acknowledge or to cite any reply from him. We repeat, it is a most unfortunate and misleading doctrine to propagate among the laity, tending to undo much of the patient work done by ophthalmologists in the education and betterment of humanity, and to renew the impression that the wearing of glasses is something to be avoided and fought against—an impression which ophthalmologists spent many years combating and overcoming. We trust that some sort of authoritative antidote will be forthcoming to Dr. Bundesen's bulletin.

Physical Therapy in the Specialties

A month or two ago we drew attention to the growing tendency in ophthalmology and oto-laryngology to relinquish their character of surgical specialties and to assume their rightful role as specialties of medicine, in which surgery is to be regarded, as it is regarded in relation to medicine at large, as an emergency measure, a sort of *dernier ressort*. Ophthalmologists and oto-laryngologists are nowadays much more concerned with the functional conservation of the organs with which they deal, and with their systemic relationships than with the perfection of operative procedures; and palliative and ameliorative measures bulk much more largely in their treatment than it ever did before in the history of the specialties.

It is interesting and suggestive to note how increasingly important a part physical therapy is playing in this trend. We would not care to go so far as to assert that the recent rapid development of physical therapy is responsible for the departure, but there can be little doubt that the possibilities offered by these modes of treatment—now for the first time being developed in the capable hands of high-grade men—make the departure practicable. Under the older system of medicine the resources of the eye, ear, nose and throat specialist for curative treatment were exceedingly meager and limited. Physical modalities have already added sensibly to these available resources, and the promise that they hold out for the future is many times greater.

One has but to glance over the contents of our own and other magazines devoted to the interests of ophthalmology and oto-laryngology to observe the steady increase of attention that is being paid to physical modes of therapy. The current literature of the specialties becomes more and more plentifully sprinkled with contributions on the subject, voicing a growing confidence in its clinical value. We would be the last to indulge in or to incite an over-enthusiastic attitude toward new and comparatively little-tried methods. Conservatism must always characterize the scientific man. But we cannot avoid the conviction that, in the hands of the men who are now developing it, physical therapy is destined to play a significant part in eye, ear, nose and throat work, and we shall watch with interest, and further as much as we consistently can, the sober discussion by which its claims must be established or disproved.

Brain Abscess and Chronic Suppurative Osteomyelitis

ASSOCIATED WITH MASTOID DISEASE

By Sydner D. Maiden, M. D., M. S., Council Bluffs, Ia.

READ BEFORE THE SIOUX VALLEY EYE AND EAR ACADEMY, AT SIOUX CITY, IA., JAN. 22, 1924.

Raymond R., age 15.

Patient first seen at hospital Nov. 29, 1920.

Chief complaint, pain in the left ear. Tenderness about left ear and some discharge from left canal. Sore throat and "bad cold in head."

Social history—negative.

Family history—negative.

Past medical history: Gives a history of repeated severe colds in head followed with profuse discharge from nose. In 1918-19 and March, 1920, had "flu" with no complications. No other serious illness. No previous trouble with ears.

Present illness began Nov. 25, 1920, with sore throat and "cold in head." Nov. 26 left ear began to pain severely and continued until M. T. ruptured the next morning. Was seen by M. D. the following day and opening in drum enlarged. Sent to the hospital the following day where he was seen by Dr. S. and myself.

Physical examination shows a well developed boy giving the appearance of being three or four years older than stated age. There was considerable tenderness on pressure about left ear, both anterior, post and below; also on manipulating the ear. No redness or edema. Tenderness over mastoid on deep pressure but no edema or redness. Canal showed considerable swelling on floor and anterior but no discharge. There was a good sized opening in post-quadrant of drum and slight pulsation could be seen in middle ear. Right ear negative for pathological findings. There was a very active sup. ethmoiditis right and left and entire naso-pharynx and pharynx highly inflamed. Acute follicular tonsilitis R. and L. Tongue badly coated.

Eyes were negative in every respect.

Neck, chest and abdomen negative.

Reflex—normal except Koernig was slightly suspicious.

Blood count, total white, 11,000. Dif. small L. 20 per cent. L. L. 1 per cent Tr. 3 P. M., 76 per cent: Urine Sp. G. 10:20. Negative for albumin, sugar.

Patient was kept in bed and attention given to nose, throat and ear as well as free elimination, etc. Second day, a profuse discharge from left ear began. Culture taken was reported with no growth. Discharge continued very profuse and patient had no discomfort and rested well during following week. His temperature was typical septic in type ranging from normal in A. M. to 102 in P. M. Repeated blood counts remained practically the same. X-ray was taken Dec. 8th and showed involvement of entire mastoid area which was quite extensive. There was still some tenderness over mastoid tip but no edema or redness. Dec. 9th a left mastoidectomy was done. Extensive cellular formation was found and cells filled with pus but no extensive necrosis was present. The inner plate over the mastoid cells just post to antrum looked suspicious and a small area of bone was removed which showed the dura to be congested with a tendency to bleed. Mastoid wound was partially closed and gauze drain inserted. Lab. reported gram positive dip. from culture. Patient was quite nauseated following the operation and dull mentally. Was not able to retain liquids per mouth until third day. He slept a great deal and was very listless when awake. On second day a spontaneous horizontal nystagmus was noticed on looking up. Patient was a little dizzy on moving head. Pupils and reflex normal except for the suspicious Koernig, as noted previously. Temp. 101.4. On third day dizziness was not so noticeable and the nystagmus on looking up was not so marked. Pupils O. K. No headache except around the wound. Temp. 100.6; pulse 70-80. Mental condition brighter. Fourth day, patient brighter and took nourishment better. Still pretty drowsy. Reflexes negative except positive Gordon and Chaddock on right and positive Gordon on left. No Babinsky right or left. Koernig remained the same. Temp. 99.2; pulse varied in night 56-76. In A. M., Dec. 14th, the fifth day, patient still slightly dull mentally. Slight word aphasia—word blindness—distinctly noticeable at times. Reflexes same as previous day. Nystagmus on looking up very slight. Pupils O. K. No diplopia. Took more nourishment. Slight headache on vertex, worse in early morning, 6-9. Temp. 98.6; pulse 60-64. Dec. 15th, patient brighter. Temp. 98.6-99.6; pulse 72-80. Dec. 16th, patient more dull in A. M. Said he had a frontal headache. Slight nystagmus on looking to right. Some spasticity of neck. Temp. 98-100.6; pulse 60-92. Was brighter on the 17th. On 18th complained of

headache over entire head. Was pretty severe during the night. Reflexes remained the same, as well as the aphasia. Temp. remained up during the night—101 at 4 a. m. and 102.4 at 4 P. M.; pulse 72-80. Mental condition quite dull. Blood count, total 17,400—S. L. 27—L. L. 1, Poly 73 per cent. Parents were told that there was evidence of intra-cranial trouble and any consultation they wished would be welcome. Dr. N. was called in that evening. Patient's mental condition took a sudden change and cleared up a great deal by the time Dr. N. examined him. Dr. N. reported no evidence of intra-cranial trouble. From then on patient made a rapid improvement—took good nourishment. Had a vertex headache most of the time and occasionally a frontal. Color was sort of pasty and pallid. Temp. ranged from 98.6 to 99.6 and pulse from 52-84, generally reaching the fifties or sixties in the early morning hours. He was allowed to be up and about the room and he gained in weight and strength. Headache was more or less constant but not severe. He had been on full diet and his appetite was very good; in fact, almost ravenous and it was necessary to watch that he did not overeat. On the morning of the 31st, three weeks after operation, the nurse reported an emesis-copious and occurring several times. Immediately following this patient became very drowsy and complained of severe headache. When seen by me in the morning he was dull mentally and complained of feeling mean all over. There was no change in any of his reflexes and no other symptoms of cerebral pressure other than his vomiting, headache and drowsiness. He had eaten a very hearty meal the night before and it was possible that it was a digestive disturbance. He was kept in bed, given a good clearing and put on liquids. That evening patient vomited while I was in the room and it was copious and projectile in type, unaccompanied by nausea. He had slept most of the day; was quite drowsy. Otherwise the same as in the morning. Pulse had ranged from 60 in A. M. to 88. Temp. 99. Blood count 23,000, S. L. 8, L. Mono. 1 Tr. 2. Polys. 89. Mastoid wound was about filled with healthy granulations and looked good. Canal had been dry since one week after operation. It was decided to wait until morning though it was quite evident that we were in for serious trouble. He had a good night. Slept soundly but woke once or twice shouting out for help. Pulse went to 54. Temp. 99. Next morning there were marked signs of intra-cranial pressure. Reflexes all gone and he was almost comatose. Invol. movements of bowels and bladder. It was decided to explore brain at once. With a Gifford's bayonet brain explorer, the dura was punctured directly above the area in postro sup. angle where the inner plate was removed at time of mastoidectomy. Was passed in for a distance of about ½ inch. No pus found. Withdrew and made another puncture about ½ inch anterior to a depth of about ½ inch with no positive findings. I returned to the sight of the first puncture and slowly penetrated to a depth of 1½ inches, when a profuse amount of pus escaped under marked pressure. About 2 ounces of thin, yellowish pus was drained from cavity. Folded rubber drain was inserted and patient left table in good condition. Culture from pus showed short chained streptococci with some tendency to dipplocci grouping. The following few days the patient ran a very stormy course. Next morning he was fairly bright. Wound was in excellent condition with a profuse discharge present. Took liquids freely but was in a stupor most of the time. Pulse was around 68-74. Temp. around 100.

Second day he was quite bright at times but slept for long periods. Pulse in the eighties; temp. stayed up to 102-103. No retention in wound. Third day there was not much change. Having some pain in the head and his mental state was very dull, semi comatose. Took liquids freely. Fourth day he was very much brighter and general symptoms were satisfactory. No signs of extension of infections. Temp. still up to 101 and 103 and pulse around 80. The rubber drain was changed to a gauze wick saturated with glycerine. Still had involuntaries. The morning of the 6th there was considerable more drainage from the wound. He was very much worse. Pulse was in the eighties and poor quality, dicrotic at times and irregular. Resp. deep and mental condition bad—in coma. Had hiccoughs during the night. Cyanotic and picture of very grave condition. Evidently an extension of process or retention in some pocket. Did not look as though he would last long. That evening of the 6th there was some improvement. Right pupil was partially dilated and light seemed to hurt the eyes. Paresis of right side of face. Temp. remained up around 102-103; pulse in the nineties. Took plenty of fluids. Involuntaries. On the 8th there was some improvement over the past three days. Temp. down to 100; pulse weak, in the eighties and somewhat irregular. Fleeting moments of brightness followed immediately by mental dullness. Would be very cyanotic for a few minutes and then would change to a marked pallor. Condition grave. On the 9th his condition was not quite so good. His temp. had dropped to 99 during the night, pulse to 60, but came up again to 102.2 and pulse 110. He was quite dull but had no signs of further extension. Drainage from wound was free. On the 10th he showed some improvement. The 11th he was much brighter in every way; the pulse had dropped to 54 in early morning but was of good quality. Drainage was not tainted with blood as it had been

previously. Talked quite rationally. Temperature had dropped to 98.4 and pulse varied from 64 to 76. The 12th he was about the same. Temp. and pulse remained down. Paresis still present. Culture showed gram positive staphylocci and chains of strep. The 13th he was about the same, a little better if anything. Temp. down to 98 and pulse 56 in A. M. Had a little more solid diet. Had been taking liquids freely. No involuntaries the last 24 hours. Since evacuating the abscess two weeks previously he had been in a comatose or semilomatous most of the time with involuntaries continuously. Drainage from wound less. Mental condition became much worse about noon. Temp. went up to 101 and he was semi-comatose again. Next morning he was brighter. Little drainage from wound. Temp. 104; pulse around 80. Looked as though there was a collection of pus in some of the ramifications of the original abscess. Still marked aphasia; paresis of right side of face and twitching of fingers on right hand. The 15th he was brighter. Pupils were equal and reacted O. K. The evening before the right pupil was dilated but reacted normally. Paresis of right side of face more marked than past few days. No retention in wound and drainage fair. Temp. dropped from 102 to 97.8; pulse from 98 to 60. The next morning he had profuse projectile vomiting followed by a general feeling of relief. Seemed bright but color was bad. Slept for long intervals. Temp. came up again and reached 102.2 during the afternoon; pulse went down from 98 to 78. Was quite bright but cerebration was slow. Did not improve as he should. Little drainage from wound. Looked as though there was retention. The 18th, no drainage. Pulse a little slow, 60 in the A. M. but good quality. Temp. 98.6. Bright mentally. The 19th, no drainage. Said head was sore all over and ached some. Condition generally good. Temp. reached 100; pulse from 68-96. The 20th, he felt good and looked better—said he felt stronger. Had a better color but complained some of vertex headache. Temp. not above 99.8; pulse 64-90. The 21st there was more drainage. Was able to pass probe a little back and then forward to a depth of 2¾ inches in wound. Strip was inserted deeply. The 22nd his condition was much better in every way. Fair drainage. Temp. and pulse fluctuated considerably. Temp. never rose above 99 but would drop below normal in the morning. This continued for the following three days. He was bright, took good nourishment and improved mentally though he slept for long intervals. The morning of the 25th, temp. reached 97, pulse 58, and he complained of soreness in the head. That night his temp. began to rise. There had been considerable drainage all along but the morning of the 26th there was a profuse amount. He was a little drowsy, temp. was 101 and pulse 84. Blood count, total 13,600; S. L. 10, polys. 90. During the day he rapidly became worse, had profuse projectile vomiting, and when seen in the evening his temp. was 105.2, pulse 128, and he was comatose. Was unable to gain much information from reflexes though there was some spasticity of neck. Pupils reacted O. K. but right was still partially dilated. Wound was dressed and profuse drainage was evident. He looked like he would last but a few hours at the most. The next morning his temperature was 104, pulse 114. He was in a very bad condition though somewhat better than the evening before; was comatose, quality of pulse good. When strip was removed from the wound there was at first a small amount of thick greenish pus which was followed with about an ounce of watery translucent fluid. This continued to drain very slowly and had all the appearance of cerebral spinal fluid. His neck was quite rigid and Koernig three plus. I decided that the destructive process had extended to the temporal horn of the lateral ventricle or to the subparachnoid space allowing the escape of cerebral spinal fluid, most likely the former, and that a general dissemination of the infection would develop throughout the brain and cord. The next morning showed some improvement and temperature and pulse were coming down. Little retention in wound and discharge was mostly watery as on previous day. Neck was movable.

Jan. 8th he was exceptionally bright. Had paresis of entire right side of body. Right pupil was dilated and numbness of right hand and foot. Rigidity of neck had about disappeared. Discharge still watery. The morning of the 30th the temperature had made a gradual recession until it reached 97.2, pulse 40. He looked fine though and said he felt good. The 31st he was bright, had a good breakfast and said he was going to make one more fight. He was very emaciated and unable to move without assistance. His condition improved rapidly from this time on. He was allowed up on back rest for 5 minutes the first of February and the time was gradually increased from day to day. He had an uneventful recovery from then on. His pulse would reach the fifties in the early morning—once to 44. Temperature stayed subnormal, 97-98 with one or two exceptions when it went to 99. The watery character of the discharge continued profusely for five days and then gradually diminished until Feb. 7th when it ceased. The discharge of pus then gradually decreased and disappeared entirely March 2nd. Culture taken on Feb. 17th showed pure growth of staphlococci. His aphasia and right sided paresis gradually became less. His memory rapidly improved so that when he left the hospital on March 9th he had simply a numbness of the third and fourth fingers of the right

hand, the ulna surface of the right forearm, the right foot and a slight paresis of the entire right side. He was examined Feb. 7th for hemianopsia and a complete right homonymous hemianopsia was present. Central vision was O. K. The wound in the dura was kept open for one week after leaving the hospital. He had no further trouble. Mental condition is normal. Paresis entirely cleared up. Strength gradually came back to normal and during the following summer regained perfect health. I saw him the latter part of August of that year. He was the picture of health in every way except for his right homonymous hemianopsia which was absolute in both eyes. I told him there was no prospect of this ever clearing up as it had been eights months since its appearance with no signs of regeneration. During the next year I heard from him and he said he was beginning to see a little in the right fields. A letter a year ago from my partner at that time informed me that his hemianopsia had cleared up entirely and this past fall was playing on the freshman football team at the University of Washington.

This case I consider of interest:

First, from the fact that it was an acute temprosphenoidal abscess secondary to an acute mastoiditis.

Second, for its extensive involvement, finally rupturing into the sinuses of the brain followed immediately by a gradually and unerupted improvement going on to recovery.

Third, that there was no permanent disability from a suppurative lesion involving the posterior limb of the internal capsule for so long a time. The hemianopsia remaining absolute for over a year and then gradually disappearing until normal vision at the end of two years.

Albert D., age 20.

First seen on Xmas day, 1922. Chief complaint, extreme dizziness with nausea and vomiting; relieved by lying down.

Family history negative.

Past history—Negative except at two years of age had severe earache, left, which lasted about a half day. When pain subsided the ear drained a heavy purulent discharge for about two weeks. When this discharge subsided he had no more trouble until he was 12 years old. At this time he again developed an earache, left, and ear drained considerably for two or three weeks. He had no more trouble until about two or three weeks before present illness. Left ear again pained for about two hours. Pain subsided and a profuse discharge followed. Ear had continued to discharge.

Present illness—On Dec. 23, 1922, he began to get dizzy and nauseated. Was relieved by lying down. No headache or pain. Called me on Dec. 25, 1922.

Examination—Examination was negative except for the following: Marked rotatory nystagmus on looking to right. Foul discharge from left auditory canal. No tenderness or edema of left mastoid. Extreme dizziness on attempting to move, nausea and sensation of falling to left. He was relieved by lying on his left side. Temp. normal. White count 12,000, polys 68 per cent. It was deemed best not to attempt any operative procedure at this time but to watch him and await for the labyrinthian symptoms to subside. Treatment was prescribed accordingly. On Dec. 27th he had a slight chill in the early hours of the morning. Temp. began to rise. Was sent to hospital at once. White count 18,000, polys 90, urine negative. Temp. 101.4, pulse 120, resp. 24. X-ray showed a sclerotic mastoid left. Radical mastoid was done that P. M. Bone was sclerotic, cells in tip and below sinus small and filled with bloody serous excudate and granulations, antrum and cells above sinus filled with cholasteatoma. Sinus was exposed by necrosis and covered with thick dark granulations that did not look healthy. Sinus was not touched. Culture was taken which showed later pneumocici. He got along fine. Dizziness and nystagmus cleared up by Jan. 1st. Blood count was normal on the first and stayed normal; blood culture negative. Left the hospital on Jan. 9th in good condition and remained so until night of Jan. 14th, at which time he developed a pain in left side of neck which passed to back of ear, then later to left side of forehead. Had slight chill. Was sent to hospital next A. M. White count 16,600, polys 88. Sinus was opened and found thrombosed at knee. Jugular was exposed and looked dull in upper half. Upper three-fourths of jugular was resected. Culture from thrombose was reported to be streptococcus. The neck wound was closed throughout and it healed by first intention. There were no postoperative complications except for a few large blebs that appeared on right leg three days after operation, which disappeared in a few days. Cultures from these blebs were sterile. His temperature and blood count returned to normal in three days and remained so. Blood culture negative. Left the hospital the morning of Jan. 31st in good condition. Mastoid wound about closed. That afternoon about 4 P. M. he developed a pain back of left eye. Pain gradually became worse and spread over frontal region and back of right eye. Was excruciating in character by 9 P. M. Had a slight chill at that time and temperature began to rise. I saw him at 11 P. M. He was crying out with severe pain in head, throbbing and lancenating. Had vomited twice profusely. Light hurt the eyes, neck was spastic, fundi were both congested but no papillitis. Reflex all exag-

gerated. Koernig positive. White count was 20,700, polys 82. Temp. 102.8, pulse 126, Resp. 24. Had marked signs of a meningeal involvement. It was decided to open the wound in the hopes of finding a pocket of pus in the obliterated sinus. He had no edema about the eyes or proptosis, so a cavernous thrombosis was not likely. No pus was found by exposing down to bulb or in the posterior limb of sinus. In the region of the knee of the sinus the mesial wall was necrotic. A pair of forceps was inserted through this area into the cranial substance about ½ inch and a large amount of dark bloody watery substance escaped. There were about two ounces of this fluid and from the location I judged it to be in the cerebropontine angle. He was in partial shock and it looked like a meningitis case. The next morning he was conscious and feeling better. His blood count was 27,000 whites and 74 polys. Culture showed diplo and short strep. His meningeal symptoms had cleared up markedly. Had a dull pain in eyes and frontal region. He had quite a stormy time for a few days. His blood count remained high for about a week. Blood culture remained negative. He left the hospital Feb. 28th feeling good with his mastoid wound healed and ear dry. He rapidly gained in strength and weight and returned to work about April 15th. He would have a slight discharge from ear at times and it was slightly tender about site of mastoid wound occasionally. This persisted and began to get more marked about May 1st. There was some swelling about the bony edges of wound and gradually became more marked and tender. Began to have some headaches. On May 22nd he was sent to hospital and wound explored. Owing to the fact that it was impossible to dress the mastoid cavity properly before the middle ear cavity and antrum were filled with granulations. Around the perifery of the wound above and posteriorly the bone was soft and spongy—sort of putty like. Previously this was sclerotic. This was all removed until healthy bone was found. Sinus was filled with organized clot. His Wassermann was negative. Whites count 15,000, polys 79. He left the hospital May 29th feeling much better. Continued to have a profuse discharge of this yellow pus from wound. Culture showed staph. and strep. There was more or less pain in left side of head, considerable headaches. Tenderness around edge of wound persisted. These symptoms gradually increased. Had constant headaches, appetite poor and was loosing weight and strength.

He again entered the hospital on July 9th with marked swelling on left side of head, profuse discharge of thick pus from ear. White count 17,600, polys 86, temp. 100, pulse 90, resp. 20. Site of old wound was exposed freely. Wound was filled with granulations. The floor of the middle fossa was necrotic. Large pieces of the bony floor were broken off with tissue forceps foreward and measilly about two inches in depth. I was afraid to go any further. The squanous portion of the temporal bone, the adjacent parital and occipital were necrotic and worm eaten in appearance. This was removed about one inch anterior to antrum, two inches superior and one inch posterior. Dura was covered with granulations and bathed in pus. He left the table in shock. Specimen of bone sent to the laboratory showed no signs of malignancy or T. B., Wassermann was again negative. He was put on massive doses of K. I. and Hg. emperically. He recovered nicely, though he continued to have pain in the head more or less and a profuse discharge from the open wound. He left the hospital July 19th improved somewhat but very weak. He failed to gain, in fact rapidly getting weaker and loosing weight. Pain in head became more constant and severe. Entire left side of head began to swell and was very edematous. Discharge from wound was profuse, thick and yellow. Was difficult for him to walk without assistance. Dr. Uren was called in consultation. We decided the only thing to do was to go in again. The next morning, July 24th, he entered the hospital with temp. 101.2, pulse 90, resp. 22, white count 14,200, polys 83. An incision was made from in front of ear up and forward almost to mid line just within the hair margin. Another was made from upper posterior margin of mastoid wound up and posteriorly well toward the mid line. Another from mid posterior margin posteriorly about 2½ inches. The scalp was elevated over this area exposing ¾ of the left half of the skull. The bone around the old site of opening to the extent of two inches was worm eaten and honeycombed in appearance. Pus oosed from this entire area. This was all freely removed which could be done very quickly by breaking off large pieces with a currette inserted between the dura and bone. The dura was covered with thick granulations and these were bathed in thick pus. At the extreme upper anterior angle of the exposure, close to the mid line a large epidural abscess was found and evacuated. It contained at the least an ounce of this thick pus. Following this he went into partial shock. The wound was left wide open. The bone about the edges looked to be fairly healthy. Iodoform strips were placed approximate to the bony edges and each day all adhesions were freed and the strips kept tight against the bone for better than six weeks. He was put on cod liver oil 1 oz. three times a day and calcium lacto phosphates. He improved rapidly in every way and left the hospital Aug. 9th feeling better than at any previous time. He went on to an uneventful recovery and feels better now that any time since he

can remember. The wound became dry about Oct. 1st and the ear also. Epithelium migrated from the lower edges of the wound across the dura so that today he has an area about three inches long and two inches wide above the ear where there is nothing covering the dura but this epithelium. He has been at work since Nov. 1st. To protect this side of his head he wears a large copper plate sewed to the inner side of his hat. I do not intend to attempt to correct this deformity for at least a year and I am undecided just what to do then, but am inclined to let well enough alone and simply free the scalp from over the site and suture it down to its original place. I would welcome any suggestions on this very much.

In a study of the literature I was able to obtain references to thirteen cases of osteomyelitis of the flat bones of the skull otitic in origin. I was able to get an abstract of but one case. This was reported by Hunter Tod of London. His case went on to autopsy and for that reason is of interest. The following is the autopsy findings:

Post-mortem report: "Fairly well nourished. Scar behind right ear. Sinuses in scalp on each parietal eminence leading to bare bone. Scalp is very thick and edematous and strongly adherent to skull all over. On stripping off the pericranium the skull bones area seen to be irregularly worm-eaten; the sunken dark red sinuous areas do not extend quite through the outer table, but in the region of the left external fontanelle is a considerable depression extending almost through the skull. At the anterior fontanelle the bone is very thin. At the posterior angle of the right parietal there is a deep depression, in the floor of which is no bone, but only periosteum and dura mater fused together. Similar boneless depressions are to be seen above and behind the right mastoid, which is practically separated from the skull. On removing the skull-cap the dura is seen to be adherent to the bone and to the periosteum at those spots where the osseous tissue is completely absent. There is no excess of cerebro-spinal fluid beneath the membrane. Beneath the tentorium covering the whole posterior fossa and base of brain is thick green pus, which also fills the left internal meatus and extends down into the spinal sheath. The bone of the tegmen tympani is red, soft and granular. Both middle ears contain soft, chessy matter. On splitting the left internal ear no pus is found in the vestibule, but the superior semi-circular canal is lost in a large cavity filled with granulation tissue. Both lateral ventricles of the brain are considerably dilated and filled with clear fluid, but the brain substance itself is pale and firm and contains no abscess."

References.

1. Notes of a case of chronic osteomyelitis of the skull, the result of mastoid disease (with specimen of calvarium). Hunter Tod, proc. Roy. Soc. Med., London, Sect. Otol., 2:37, 1908-9.

2. Osteomyelitis of the temporal and adjacent bones of the skull as a sequel to otitis media suppurative. C. W. Richardson, Arch. Otol., 33:1-7, 1904.

3. Osteomyelitis of flat skull bones following inflammation of the nasal sinuses and of the middle ear. R. Schilling, Ztschr. f. Ohrenh., 48:52-100, 1904-1905.

4. Two cases of osteomyelitis of the flat bones of the skull following suppuration of the ear. Guisez (Paris) Arch. inter de Laryngol., Paris, 20:725-732, 1905.

5. Osteomyelitis of flat bones of skull following otitis and suppurative sinusitis. J. Guisez, Arch. internat. de laryngol., 22:1-22, 1906.

6. Otic osteomyelitis of the flat bones of the cranium. J. Moller, Hosp. Tid., Copenh., 4R., 15:1333-1344.

7. Three cases of cranial osteomyelitis of otitic origin. Vignard and Sargnon, Prov. med., 21:96, 1910.

8. Osteomyelitis of the cranium of oticic origin. Lannois, Lyon med., 118:1269-1271, 1912.

9. Temporo-parieto-occipital osteomyelitis of auricular origin. R. Hahn, Arch. ital. diotol., 23:372-394, 1912.

10. A case of temporo-occipital osteomyelitis of otitic origin. L. Buttafochi, Atti do clin, otorino-laringoiat. d. r. Univ. di Roma, 16:293-308, 1918.

Traumatic Cataract

In traumatic cataracts, or following extraction in which there is a large amount of soft substance, there does exist a possibility that one may hasten the process. Since it has been repeatedly proven that autolysis proceeds more rapidly in acid solution, some cases of traumatic cataract were given a weak acid solution to use in the eyes at frequent intervals, and in some it did seem as if the absorption of the soft lens was more rapid, but this is difficult to prove satisfactorily. Another point which may be of considerable value is that the proteolytic ferment in the aqueous seems to be in much larger amounts, following frequent puncture of the anterior chamber, so that in view of this fact it would seem that frequent needling with emptying of the anterior chamber would be of value in hastening the process.

The question of introducing a small quantity of an active proteolytic ferment into the lens capsule by means of a syringe or other hollow needle is among the possibilities but hardly within the probabilities.

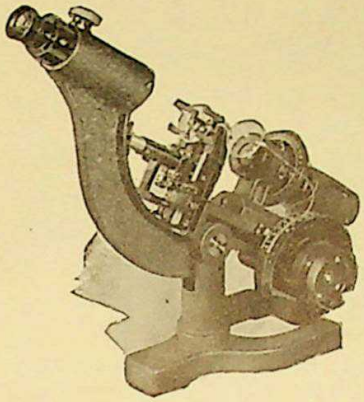

DEPENDABLE *Prescription* SERVICE

Verified on the Lensometer

Quality and durability are strikingly manifest in every product of the Dow Optical Company. Materials of the first quality combined with modern scientific methods of construction insure a product that will perform unfailing service.

Strict and accurate adherence to every detail of each prescription, by expert workmen, rightly justifies complete confidence in our work.

Practical and intensive cooperation as practiced by each member of our organization in the handling of prescriptions makes possible a quality and accuracy of service that insures permanent satisfaction.

DOW OPTICAL COMPANY

Thirty North Michigan Avenue, CHICAGO

W. E. DOW, President

Your Prescriptions are Accurately Filled

DEALERS IN OPHTHALMOLOGICAL INSTRUMENTS

can remember. The wound became dry about Oct. 1st and the ear also. Epithelium migrated from the lower edges of the wound across the dura so that today he has an area about three inches long and two inches wide above the ear where there is nothing covering the dura but this epithelium. He has been at work since Nov. 1st. To protect this side of his head he wears a large copper plate sewed to the inner side of his hat. I do not intend to attempt to correct this deformity for at least a year and I am undecided just what to do then, but am inclined to let well enough alone and simply free the scalp from over the site and suture it down to its original place. I would welcome any suggestions on this very much.

In a study of the literature I was able to obtain references to thirteen cases of osteomyelitis of the flat bones of the skull otitic in origin. I was able to get an abstract of but one case. This was reported by Hunter Tod of London. His case went on to autopsy and for that reason is of interest. The following is the autopsy findings:

Post-mortem report: "Fairly well nourished. Scar behind right ear. Sinuses in scalp on each parietal eminence leading to bare bone. Scalp is very thick and edematous and strongly adherent to skull all over. On stripping off the pericranium the skull bones area seen to be irregularly worm-eaten; the sunken dark red sinuous areas do not extend quite through the outer table, but in the region of the left external fontanelle is a considerable depression extending almost through the skull. At the anterior fontanelle the bone is very thin. At the posterior angle of the right parietal there is a deep depression, in the floor of which is no bone, but only periosteum and dura mater fused together. Similar boneless depressions are to be seen above and behind the right mastoid, which is practically separated from the skull. On removing the skull-cap the dura is seen to be adherent to the bone and to the periosteum at those spots where the osseous tissue is completely absent. There is no excess of cerebro-spinal fluid beneath the membrane. Beneath the tentorium covering the whole posterior fossa and base of brain is thick green pus, which also fills the left internal meatus and extends down into the spinal sheath. The bone of the tegmen tympani is red, soft and granular. Both middle ears contain soft, chessy matter. On splitting the left internal ear no pus is found in the vestibule, but the superior semi-circular canal is lost in a large cavity filled with granulation tissue. Both lateral ventricles of the brain are considerably dilated and filled with clear fluid, but the brain substance itself is pale and firm and contains no abscess."

References.

1. Notes of a case of chronic osteomyelitis of the skull, the result of mastoid disease (with specimen of calvarium). Hunter Tod, proc. Roy. Soc. Med., London, Sect. Otol., 2:37, 1908-9.

2. Osteomyelitis of the temporal and adjacent bones of the skull as a sequel to otitis media suppurative. C. W. Richardson, Arch. Otol., 33:1-7, 1904.

3. Osteomyelitis of flat skull bones following inflammation of the nasal sinuses and of the middle ear. R. Schilling, Ztschr. f. Ohrenh., 48:52-100, 1904-1905.

4. Two cases of osteomyelitis of the flat bones of the skull following suppuration of the ear. Guisez (Paris) Arch. inter de Laryngol., Paris, 20:725-732, 1905.

5. Osteomyelitis of flat bones of skull following otitis and suppurative sinusitis. J. Guisez, Arch. internat. de laryngol., 22:1-22, 1906.

6. Otic osteomyelitis of the flat bones of the cranium. J. Moller, Hosp. Tid., Copenh., 4R., 15:1333-1344.

7. Three cases of cranial osteomyelitis of otitic origin. Vignard and Sargnon, Prov. med., 21:96, 1910.

8. Osteomyelitis of the cranium of oticic origin. Lannois, Lyon med., 118:1269-1271, 1912.

9. Temporo-parieto-occipital osteomyelitis of auricular origin. R. Hahn, Arch. ital. diotol., 23:372-394, 1912.

10. A case of temporo-occipital osteomyelitis of otitic origin. L. Buttafochi, Atti do clin. oto-rino-laringoiat. d. r. Univ. di Roma, 16:293-308, 1918.

Traumatic Cataract

In traumatic cataracts, or following extraction in which there is a large amount of soft substance, there does exist a possibility that one may hasten the process. Since it has been repeatedly proven that autolysis proceeds more rapidly in acid solution, some cases of traumatic cataract were given a weak acid solution to use in the eyes at frequent intervals, and in some it did seem as if the absorption of the soft lens was more rapid, but this is difficult to prove satisfactorily. Another point which may be of considerable value is that the proteolytic ferment in the aqueous seems to be in much larger amounts, following frequent puncture of the anterior chamber, so that in view of this fact it would seem that frequent needling with emptying of the anterior chamber would be of value in hastening the process.

The question of introducing a small quantity of an active proteolytic ferment into the lens capsule by means of a syringe or other hollow needle is among the possibilities but hardly within the probabilities.

Principles of X-Ray Therapy in Chronic Pharyngitis and Tonsillitis

By W. D. Witherbee, M. D., New York City

The tonsils and adenoids as well as the adjacent structures involved in infections of the throat are composed of lymph tissue supported by a fibrous frame work. Lymphoid tissue in its simplest form is defined by Barnes as a reticular connective tissue with a greater or less number of lymphocytes in its mesh. These lymphocytes cannot be distinguished from those in the blood. The lymphocytes may be scattered diffusely in the reticulum or may be closely packed within a circumscribed area. The former is the simple or diffuse lymphoid tissue, while the latter, in which the reticulum assumes a definite form, is called a lymph follicle. The lymph follicle contains lymphoblasts with mitotic figures of the nuclei indicating the presence of embryonic tissue.

The changes in the chromatin of the nucleus of the lymphocyte is the first indication of the effect of irradiation. This is followed by degeneration and absorption of the cell which differs in no way from that of any other destructive process. The number of cells affected and the time the process of destruction and absorption takes place depends on the amount of irradiation absorbed by these tissues. Investigators who have removed the tonsils and adenoids some weeks or months after X-ray treatment report that they are unable to find any evidence of active destruction of lymph tissue. The time for such investigation should be when shrinkage and drainage is actually taking place and not after the cells destroyed by the X-ray have been absorbed.

Clinically these same radio-sensitive lymph structures play an important role in the various forms of leukemia, Hodgkins disease and lymphosarcoma. The destruction and absorption of these cells with consequent shrinkage of the tumors in these cases are well established. Furthermore, the destruction of lymphocytes in the circulating blood as proven by blood counts taken before and after X-ray exposures indicates that the lymphocytes imbedded in the lymph structures involved in infections of the throat may also be destroyed by the X-ray. This absorption of lymph elements produces not only a shrinkage from within but promotes eversion and drainage of the infected crypts. Quite the reverse of sealing the crypts by the application of caustics to the mucous surface.

Another important factor in the effect of X-ray on infected tissue other than shrinkage and drainage is the bio-chemical changes produced in the area exposed to irradiation. The results obtained in the past in the various infections of the skin and tubercular glands and more recently in diphtheria carriers, erysipelas, acute and sub-acute suppuration in pneumonia, malaria, acute and subacute sinusitis, pyorrhea and pertussis indicate that the X-ray produces changes in the tissues which interfere materially with the progress of the invading bacteria. This is further emphasized in the results obtained by X-ray therapy in chronic pharyngitis and tonsilitis in which 80 per cent of those treated have been relieved of this condition, having been under observation for from one to three years.

Some of the cases after receiving X-ray treatment have had their tonsils removed because the examiner has found on culture various forms of pus micro-organisms present. The bacterial flora of the throat before and after operation according to Pilot, Pearlmann and Davis remains the same, the only difference being a few less colonies after the operation. Cultures made from throats after X-ray treatment have been free from pathological micro-organisms from a few days to several months. Sterilization of the throat or the rectum is obviously impossible. The washings from the mouth and discharges coming from the nasal fossa are constantly bathing and contaminating these areas. The mere presence of pus bacteria is then no indication for operation or X-ray therapy except in diphtheria carriers.

The permanency of X-ray effects on the tissues involved in chronic pharyngitis and tonsilitis has been determined by the examination of the throats of those individuals who have been treated for tubercular glands of the neck during the past ten years.

The tissues infected in cases of chronic pharyngitis and tonsilitis are not only the tonsils and adenoids but the lingual tonsil, infra-tonsillar nodule, lymph nodes on the lateral and posterior walls, lymph tissue in the fossa of Rosenmuller and the cervical glands. Hence the operation at best removes only part of the tissues involved. Successful results following operations depend not only on the patient's power of endurance to withstand the operation but his resistance to overcome the infection remaining in the adjacent structures. This is true of any procedure directed

This paper was read before the American Roentgen Ray Society, and is published here simultaneously with its appearance in the American Journal of Roentgenology and Radium Therapy, by Courtesy of that Journal.



solely to the tonsils and adenoids. A large percentage of patients treated by X-ray give a history of from one to three operations for the relief of this condition.

None of the complications or contraindications in the surgical removal of tonsils and adenoids interfere in any way with the judicious use of X-ray therapy. The improvement noted in some forms of deafness is no doubt due to the relief of pressure on the eustachian tube by the shrinkage of the lymph tissue in the fossa of Rosenmuller.

The shrinkage and drainage of the structures involved in chronic pharyngitis and tonsilitis are dependent on the relative amount of radio-sensitive cells and fibrous tissue present. The large soft tonsil reveals the most spectacular results. The small fibroid tonsil containing relatively less radio-sensitive tissue and being smaller in size, the change is less marked. The fibroid tonsil has undergone fibrous degeneration, indicating that the infection is chronic in character and more or less controlled by the fibrous process as exemplified in other forms of infection. This type of tonsil is often imbedded in infected tissue and associated with a marked infection of the adjacent structures from which absorption is taking place to a greater extent than from the fibroid tonsil itself. All large tonsils are not soft; some are firm and fibrous. Neither are all small tonsils fibrous, some being soft and show marked reduction in size.

A brief review of the literature indicates the extent and possibilites of X-ray therapy in the various forms of infection.

A small dose of X-ray frequently applied is the recognized standard of treatment in dermatology of acne, lupus vulgaris, carbuncle, furunculosis and various other infections of the skin.

Hickey of Ann Arbor and later Kahn of Detroit have been able to clear the throats of diphtheria carriers in from two to four days after a fractional dose of X-ray. These results were obtained in 80 per cent of the cases treated.

Schrader of Berlin reports his results in seven cases of erysipelas which were uniformly good. Complications (inflammation of the kidney) occurred in only one instance in which irradiation could not be begun until several days after the

eruption of the erysipelas. The dose was one-sixth of an erythema dose. The day following the irradiation the reddening became less marked and the swelling died down.

Kemp of Leipzig reports the healing under Roentgen treatment of a circumscribed peritoneal suppurative process originating from an appendix or consecutive to abortion. Furuncles in the axilla also subsided under Roentgen exposures after a small incision. Leg ulcers rebellious to other measures cleared up promptly. Pneumonia which seemed to suggest subacute or chronic suppuration was favorably influenced in several cases. A single large field was exposed, using 20 to 40 per cent of an erythema dose.

The Italian official commission for the study of Roentgen-ray treatment of malaria states that this treatment is contra-indicated in acute malaria. Large doses may bring on a severe attack with extensive invasion of the blood stream by the parasites. Chronic enlargement of the spleen frequently subsides under irradiation. Some forms of malaria with infrequent attacks may be cured by Roentgen treatment without drugs. The quinin-resistant forms should be treated with quinin again after the use of the Roentgen rays.

Van Roe of Amsterdam, Holland, reports 470 cases of glandular lesions of the neck, axilla and groin. Improvement was realized in every instance and clinical cure in 85 per cent in a few months. The malignant type which develop fistulas early are more rebellious to Roentgen rays and usually require preliminary surgical measures. The benign type may be larger but retrogress under a few exposures. A cheesy agglomeration of lymphomas may require six or eight exposures at three-week intervals and after this a few treatments at three-month intervals. The cheesy matter can be asperated through a large needle or if located in a single gland can be incised. An abscess of the painless or benign type can be punctured during the exposures at three-week intervals. Incision of the abscess is not advised. In the other types the painful glandular process if solitary should be excised, followed by six X-ray exposures. When combined with an abscess, incision is indicated with one exposure a week; never over red skin. The result is generally a scar and sometimes a fistula. When the abscess has already broken through the skin he recommends ample opening of the gland, scraping out the cheesy masses followed by a few exposures at three-week intervals. Improvement occurs immediately and invariably after exposure of the tuberculous gland, but bone and joint processes are not amenable except those in small bones of the hand and feet which give very favorable results. Amputation of fingers and toes is no longer necessary. Tuberculous processes in ribs, sternum and skull bones may be favorably influenced by radiotherapy. If there is a fistula it should be curretted and the exposure will complete the cure. He believes that tuberculous epididymitis responds to the Roentgen rays as favorably as the glandular process.

Osmond of Cleveland says that X-ray offers a method of preventing the acute catarrh condition of the sinuses and antrum from becoming purulent and the acute purulent sinusitis from becoming chronic. Chronic suppurative sinusitis with granulations, polypi or necrosis of bone is the end result of the acute condition which every method of treatment seeks to avoid.

Garretson of Buffalo believes that infiltration of the lymphatic tissue of the peridental membrane of the teeth and the gums is the greatest factor in recurrent infections from pyorrhea. He has found that if these lymphatic areas are treated by X-ray that absorption takes place, pressure is relieved and the tissues recover.

Twenty-six cases of active pertussis were given Roentgen-ray treatment by Bowditch and Leonard. The ages of the patients varied from 3 months to 40 years. The patients were in different stages of the disease, varying from 1 to 10 weeks. Each patient received three or four applications of the Roentgen ray at intervals of 2 or 3 days. The dosage was regulated according to the age of the patient and the total amount of Roentgen ray given to any one patient was well under an erythema dose. There has resulted definite improvement in those patients which the authors state cannot be explained by mere accident. In a small percentage of these 26 cases after two or three applications of the Roentgen ray covering a period of six days, the spasms and whoops entirely disappeared and the patients were clinically well except for possibly a very slight cough. The bulk of the patients were "relieved." There was a gradual diminution in the number of spasms.

Irons of Chicago believes that aside from the chronic suppurative lesions of the lungs which may be the source of distant metastases, there is an interesting group of cases in which the primary lesion is apparently at the hila of the lungs and in which other areas of chronic infection can be excluded with reasonable certainty. These cases have been more numerous in the years since influenza has been epidemic.

The clinical features of this group are: Recurrent arthritis; attacks of erythema with nodular swellings resembling clinically erythema nodosum of erythema multiforme; frequently asthmatic seizures in adults not previously subjects of asthma, and definite peribronchial thickening, particularly of the lower lobes, with sometimes enlargement of the lymph nodes at the hilum of the lung, as shown by fluoroscopy and roentgenograms. The erythema, arthritis and asthma may

occur singly or together. The pulmonary condition has usually followed bronchopneumonia and is not tuberculous. Periods of irregular fever of from 100 to 103, lasting from a few days to a week, occur, and with these febrile attacks come the erythema and arthritis. There is a moderate leukocytosis. Blood cultures, both aerobic and anaerobic, during the exacerbations of fever have usually shown growth. Apparently the infection is resident in the peribronchial tissues and lymph nodes at the hilum of the lung and is therefore to be regarded as an unusual type of infection resident in the local lesion rather than as a renewed invasion of the body through the respiratory mucous membranes. The diffuse erythema and asthma suggest a protein intoxication possibly derived from the infecting bacteria or from the tissues effected by them. Several of these patients have been greatly benefited by therapeutic doses of the Roentgen ray directed toward the tissues at the hila of the lungs.

Conclusions.

X-ray therapy given previous to operation materially lessens the amount of dissection necessary for the removal of tonsils, thereby decreasing possibility of complications.

X-ray therapy is recommended in cases where an anesthetic or operation is contraindicated. Also:

1. Those cases past middle life where hemorrhage may cause complications due to a mild or severe arteriosclerosis.

2. Patients whose tonsils are imbedded in infected tissue in which the operation may cause dissemination of septic emboli into the blood and lymph streams.

3. Patients whose adjacent lymphatic structures (not removable by operation) are markedly infected.

4. Patients suffering from chronic cardiac lesions, Brights disease, diabetes, exophthalmic goiter, chorea, rheumatism, hemophilia, asthma, tuberculosis, status lymphaticus or any condition which has lowered the patient's general resistance.

Ossification in a Chalazion

Frederick C. Cordes, in the *Journal* of the A. M. A., reports the following case:

History—J. M., a man, aged 38, reported to the clinic, April 26, 1922, complaining of poor vision and inflamed eyes. He had had chronic inflammation of both lids for the last fifteen to eighteen years. The condition had improved at times only to become aggravated on slight irritation, as by wind or dust. Within the present year, the lids seemed worse and the eyes watered a great deal. For the last seventeen years the patient had noticed a swelling or lump in the right lower lid. This began as a stye, which did not come to a head, but gradually increased in size over a period of several months. Since that time it had not changed materially. It was not painful or tender but, as it had become large with a tendency to make the lid heavy, the patient requested that it be removed. The vision of the right eye had been poor for the last eighteen years; the loss of sight was rather sudden and had remained unchanged. The eye had never been inflamed or painful.

Examination—Vision of the right eye was limited to counting fingers at 10 feet; of the left eye, 0.5. Examination of the right eye revealed mild ectropion; the conjunctiva reddened and velvety in appearance with considerable swelling, and no follicles or scars present. In the lower lid midway between the canthi and below the ciliary margin was a tumor mass which was firm, not tender, and not adherent to the skin. On eversion of the lid, the mass presented under the conjunctiva. Examination of the cornea, anterior chamber and iris was negative. The fundus presented small lenticular opacities, and floating opacities in fluid vitreous; the disk was not remarkable; in the macula region was an old degenerative process.

The left eye presented mild ectropion; the conjunctiva appeared as described above. Examination of the cornea, anterior chamber and iris was negative. The fundus presented floating opacities, fluid vitreous, and several scattered spots of old choroiditis; the disk was not remarkable.

The lid condition was diagnosed as chronic catarrhal conjunctivitis, with fibroid chalazion of the right eye.

The chalazion was excised through the conjunctival surface in the usual manner. On cutting through a dense fibrous layer, the instrument grated against a bony-like substance. The mass was dissected free from surrounding tissues and removed. Because of its apparent bony structure, the mass was decalcified, and microscopic sections were prepared. Examination of these showed true ossification with the usual haversian systems present.

The MONTHLY is a specialized magazine for a definite field—and both the field and the magazine are yours.

An Unusual Nasal Polyp

By W. H. Gestweit, Jr., M. D., San Diego, Cal.

While nasal polypi are a rather frequent finding, the literature of the subject is quite meager, only eleven articles being listed in the Cumulative Index since 1916, three of which are limited to radium and X-ray treatment. Single polypi of considerable size are regarded as arising as polypoid or edematous tissue in the antrum and extending through its estium, being pulled through by the suction exerted during inspiration. Viewed structurally, they vary from a more or less fibrous tissue to a very soft, edematous or myxomatous structure, pale and glistening in character with a slight perivascular small-celled infiltration. They usually present posteriorly and are single. The surface epithelium varies from columnar to single squamous layers with erosions due to pressure or infection. Cystic areas are often present but they are lined with endothelium of the expanded lymph channels and not with epithelium, so they are not true cysts. The absence of pain is almost characteristic. Of the 35 cases seen at the Royal Infirmary, Edinburgh and reported by Ewing, only 9 complained of any discharge, and on examination only three showed any pus. In diagnosis, transillumination proved of value in only 14 cases, the rest being clear or even the affected side showing clearer than the unaffected.

The case to be reported presents some rather unusual features that make it seem worthwhile to call attention to it.

The patient, a young woman, complained of left sided nasal obstruction, aggravated by a cold. No discharge, no pain. Since the age of twelve she had been troubled by the same condition relieved by the removal of polypi, seven times in all. The last operation was three years ago. The present trouble had been coming on for about five months. She had always been free from colds until obstruction manifested itself. No cause could be remembered as starting the trouble, the onset being apparently spontaneous. General health always good, except for the usual diseases of childhood which cleared up uneventfully.

Examination showed the left nasal cavity filled with a grey edematous mass, slightly movable, and apparently attached somewhere beneath the middle turbinate, the exact point being undeterminable. There was a slight excess of mucoid secretion. Transillumination negative.

Under local anesthesia, the growth was avulsed, bringing away a large sessile polyp about 2½ cm. in diameter. The patient said she couldn't breath through that nostril yet, and another polyp farther back was seen to completely block the nose. This was removed in the same manner with a gush of clear straw-colored fluid. This polyp contained a cavity 2x3x3 cm. with a solid end about 2 cm. in diameter. Extending from the upper part of the sac was a thin pedicle about 1½ cm. long.

Due, as I believe, to the prolonged pressure



exerted by the various growths, the septum bowed over almost completely blocking the right side of the nose. However, the etiology may be the reverse. The left middle turbinate stood out at right angles to the lateral wall. Otherwise the nose appeared normal. The patient refused any other operative interference (septal resection or antral investigation). She remarked that this was

the first time that the polyps had been "yanked" out with their pedicles. It is hoped that there will be no recurrence since no shreds of tissue could be seen remaining.

Aside from the size of the growths, the microscopic picture is unusual. All previous reports deny the presence of true cysts in nasal polypi, except that of Levy. The findings of Dr. R. J. Pickard, who examined the tissue is as follows.

"Tumors from the nose: one, 2 cm. in diameter: one, 6 cm. long, 2.5 cm. in diameter, constricted near the base. (Done by the snare). The tumors are soft, translucent, grey. On section a watery fluid is squeezed out of the growths on the slightest pressure. There is a large cystic cavity in the larger growth. Microscopically the tumors show fibroblasts with collagen fibers separated by wide spaces from each other except near the base of the tumor, which is more solid, less oedematous, and has numerous blood vessels. There is infiltration with round cells and easinophiles, endothelial cells are less numerous. Polynuclears are more numerous in the areas with the most oedema. In the pendant parts of the tumors, the fibroblasts are star shaped, and there is mucin in the interspaces. The covering is a stratified prismatic epithelium. No glands seen in the sections. The cyst wall is lined with columnar epithelium with a well defined basement membrane. "Diagnosis-polyps."

1200 1st Nat'l Bk. Bldg.

Dawson, G. W.: Lancet 1:1095-6, June 3, 1923.

Albright: U. S. Naval Med. Bu., 19:169. August, 1923.

Syme, W. S.: Jour. L. R. & O., Dec., 1916.

Ballenger, W. L.: Diseases of the Nose, Throat and Ear. 1914.

Phillips, W. C.: Diseases of the Ear, Nose and Throat. 1923.

Meniere's Syndrome Caused by Allergy

W. W. Duke, in the Journal of the American Medical Association, after reporting two illustrative cases, presents the following comment and conclusions:

In the two case histories reported here, these facts are of interest:

1. In each case the patient had the classical symptom complex known as Ménière's syndrome.

2. In each case the patient had a marked case of allergy.

3. In each case the Ménière complex was relieved by epinephrin.

4. In each case the Ménière complex was partly or wholly relieved over several weeks' trial by the avoidance of foods to which the patients gave positive intracutaneous tests.

5. In each case Ménière's syndrome was reproduced during a well period by the intracutaneous injection of extracts of the foods to which the patients showed skin hypersensitiveness and by the eating of such foods.

This, it seems to Duke, is convincing evidence that allergy is one of the several causes of the symptom complex known as Ménière's syndrome.

Reactions of allergy may be divided roughly into two classes: (1) contact allergy, that is, reactions which occur as a result of direct contact between an allergen and a surface to which it is hypersensitive; and (2) general allergy, that is, symptoms which occur as a part of a general reaction after an allergen has been absorved and distributed by the blood.

In both of the cases reported the reaction with symptoms that were characteristic of Ménière's syndrome occurred as part of general reaction to foods which were either eaten or injected intracutaneously. That these symptoms could occur as a result of a contact reaction would seem theoretically improbable, since in this type of allergy it is rare that an offending allergen is absorbed in quantity sufficient to give rise to a general reaction. In these patients, symptoms occurred apparently only after the eating of foods which could be absorbed in quantities sufficient to give rise to general symptoms.

In this paper the author has reported the history of two patients subject to repeated acute attacks of dizziness, tinnitus, nausea and vomiting, which were classical examples of the symptom complex known as Ménière's syndrome.

Each patient had a chronic history of allergy, each was proved hypersensitive to foods, each was relieved both by the use of epinephrin and by the avoidance of the foods to which they had skin hypersensitiveness, and in each the symptom complex was reproduced during a well period both by the intracutaneous injection of extracts of the foods to which they showed skin hypersensitiveness and by the eating of such foods.

It is suggested that allergy is one of several important causes of the symptom complex known as Ménière's syndrome.

NOTE.—Since sending this paper for publication, the author has observed three additional patients who were subject to attacks of dizziness associated with asthma or hives and were definitely allergy cases. The condition therefore is not extremely rare.

Reform Diet in Ophthalmic Diseases

George H. Bell, in the *American Journal of Ophthalmology*, declares that there is a growing demand for a scientific supervision of the diet in health and disease, and an increasing realization of its importance. Hence my great interest in "dietary reforms." He emphasizes the importance of using certified raw milk, and of eating raw fruits, green vegetables and salads. Again, certain important substances occur in animal fats which should form a part of the diet, such as fats from meats, butter and cream. We should consume at least one quart of milk or its equivalent in dairy products every day, and raw food and raw fruits should be eaten as salads and desserts once or twice daily to insure the required amount of vitamins. It seems that in the course of cooking or drying something essential is destroyed. We ought every day to eat freely of some leafy vegetable food such as spinach, cabbage, beet tops, brussels sprouts, lettuce, dandelions, pepper-grass and Swiss chard. They have unique properties. The consumption of these leafy vegetable foods will go far towards overcoming constipation.

The author has so arranged the "reform diet" that milk can be taken at the proper time. He is a firm believer in the food value of milk, the most desirable single article of food for infants and children, and being more and more appreciated by adults. Funk was the first to suggest the relationship between the composition of the milk, and some deficiency diseases in children. Funk stated that on heating milk certain vitamins become more or less completely destroyed. Therefore great advantage lay in a certified raw product, safeguarded from contagious diseases and containing a more or less constant fat content. Milk taken with the ordinary meals frequently causes catarrh, because of overeating and overloading the stomach. Milk must be taken with a starch or fruit, and not with a full meal, because one quart of certified raw milk is a meal in itself. A hearty eater, who drank about two glasses of raw milk with each meal, three times daily, developed a catarrhal state, followed by intestinal toxemia and keratitis of both eyes. Bell found his tongue heavily coated, his breath very foul and his urine loaded with indican, also he was a sufferer from constipation. His teeth were apparently healthy. He was able to extrude pus from his tonsils.

Examination of his eyes showed Mooren's ulcer of right eye and incipient ulcer of the left. The ulcer in the right eye had developed from the margin of the cornea above, and had extended all the way around the cornea. The gray, cloudy margin of the ulcer was undermined and could be elevated. Moreover, there were marked inflammatory complications. He had been treated for six weeks by an ophthalmologist. This oculist had cauterized the ulcer with carbolic acid several times and had used the actual cautery, also hot fomentations and atropin were being used. All Bell did for him was to have his tonsils enucleated at once, put him on his "reform diet" with hot applications to his eyes—bichlorid vaselin—1-5000 in both eyes night and morning, and atropin solution in his eyes occasionally; while his colon was thoroughly emptied every day by means of an enema of water at blood heat. This patient made a good and rapid recovery, and returned to his native state in two weeks, where he continued the treatment for four weeks more. Doctor H. A. Wakefield of Charlotte, North Carolina, in a letter recently, said that Mr. B. now had normal vision in both eyes.

Rule of the Reform Diet.

The principle of the reform diet is simple and very plain. Not to mix heavy starches and proteins at the same meal.

Heavy starches—Bread, whole wheat, white corn or rye, and crackers. Potatoes, rice, macaroni, corn, lima beans, dry beans, and also sugar.

Heavy proteins—Meats of all kinds, fish, shell fish, chicken, duck, turkey, eggs and cheese.

Bell has arranged a "Diet Sheet" but one may make his own, if he does not violate the rule and principle. This system of diet, which he can strongly recommend, is in no respect a radical one. It includes the best features of several types of diet. Eat any kind of food you like or choose, provided you eat it at the right time.

McCollum says that in the last century changes in the habits of the population of Europe and America have brought about changes in diet. The changes have been in favor of highly milled cereal products, muscle meats, potatoes and sugar. *This diet is a failure* in animal experimentation and is proving a failure in human experience. Evidence that this is true is abundantly supplied in the percentage of underweight children in our schools and in the prevalence of rickets, small jaws, and teeth which are irregular, poorly developed and which decay easily. Personally, Bell is convinced that there is something wrong with our way of living. McCollum has proved it with animals, and Bell's experience with this reform diet over a period of years, in his clinics and with his private patients, coincides exactly with his findings. It is a never ending fermentation in the stomach and putrefactive condition in the intestines, brought about by wrong food combinations, bad teeth, and diseased tonsils, that is destroying the human race. We must not lose sight of the fact that toxemia ranges in intensity from an ordinary cold to severe acidosis. And also do not forget that we can have excessive fermentation as well as excessive putrefaction in the same individual and at one and the same time.

Liquefaction and Absorption of the Crystalline Lens

C. A. Clapp, in the *American Journal of Ophthalmology*, discusses this subject at length. He believes that the experiments of Goldschmidt and Clapp show, first, that the aqueous has a proteolytic ferment, which in itself is capable of breaking up albuminoids into simpler compounds, and further, that there is a definite autolytic action of lens proteid itself. Now the possible explanation of the method of causing the insoluble lens proteid to undergo solution with final absorption is somewhat as follows: As soon as the capsule of the lens is ruptured, which is nearly always associated with rupture of some of the lens fibers, there is an entrance of aqueous as well as the lens lymph into contact with contents of the fiber, which had been previously in a sealed package. This immediately causes a diffusion of the soluble proteids with a precipitation and opacification of the insoluble, which, under the combined influence of the autolytic ferment and the proteolytic ferment in the aqueous, undergo a rather slow digestion with production of simpler compounds with smaller molecules, which can pass through an animal membrane, thus being able to enter the canal of Schlemm or other channels and be carried into the circulation. This action is almost surely a combination of the proteolytic ferment of the aqueous and the autolytic of the lens, nevertheless from our previous experiments, Clapp believes we are justified in the conclusion that this is the mechanism of solution.

Morgagnian Cataract.

This seems to be explained upon the theory of autolysis much more readily than upon any other hypothesis.

In this condition the capsule is not ruptured, but following the occurrence of the opacity there is a rupturing of the fiber membrane and the beginning of selfdigestion, which proceeds very slowly until finally the greater part of the lens is softened and rendered more or less liquid, while the nucleus being older and more sclerosed remains, settling down in the lower part of the capsule. Although a large part of the fluid contents are slowly absorbed, there often remains a very dense secondary or membranous cataract. In case the condition occurs early in life, as is sometimes seen, there is no nucleus, but a more or less caseous mass, which cuts like cheese and which finally absorbs to a membranous curtain. While there are a few reports in the literature of a traumatic cataract without rupture of capsule going on to complete absorption, the weak point in these cases is that it would be almost impossible to detect a small rupture far in the periphery, or even posteriorly, by any of our known methods.

The Question of Senile Cataract.

Many have been the explanations for this condition and possibly the question will always be in a more or less speculative state. The factors which impress themselves most profoundly upon the writer are: That the lens is more or less a tissue that has been extruded or thrown off by the body; that each cell or fiber is surrounded by an animal membrane that is under a certain amount of osmotic pressure; that with variations in the concentration and chemical composition of the surrounding fluid, or lens lymph, this pressure may be so great that a small rupture in this membrane would occur allowing the nourishing fluid to enter into the fiber with the resulting precipitation of the insoluble albuminoids, which seem to be in greater abundance in the nucleus rather than in the cortex of the organ. The condition once beginning would start a vicious circle by swelling, pressure, and change in the concentration or osmotic pressure of the surrounding fluid, thus extending the process.

Just why the lower nasal quadrant is so frequently the first to show beginning opacity will probably be found in the current of the nutrient fluid or in changes in the epithelium beneath the capsule.

Certainly the cases of spontaneous cure, with absorption of the lens, can be explained better by means of this theory than any other.

The question of other forms of cataract might find some means of explanation from these theories, but their number is such that to discuss each variety here would require too much space.

Treatment.

Following the author's experiments as to the cause of liquefaction, there immediately arises the question, that if this is a case of autolysis, does it add any new knowledge that can be used in the treatment of these conditions?

As to the senile and other cataracts of similar nature, where the amount of insoluble albuminoid is large and in a more or less sclerosed condition, it seems that this theory may offer some means of explanation as to their cause, but hardly any for their solution; nor can we see where any of the so-called modern methods of treating incipient cataracts by aiming to arrest their development, will be explained by this hypothesis. The effect of radium in causing lenticular opacities to become stationary, if it occurs, is not explainable on this basis. The question of intermittent use of dionin, glycerin, mercury cyanid, saline, etc., might, by increasing the flow of lens lymph, tend to cause the condition to remain stationary.

ABSTRACT OF PROCEEDINGS
OF THE
ROYAL SOCIETY OF MEDICINE
Sections of Ophthalmology and Oto-Laryngology

Abstract Editor:
FAYETTE C. EWING, M. D.
Alexandria, La.

Original Fellow of the Royal Society of Medicine, London, England; Major-Chief, Eye, Ear, Nose and Throat Department, U. S. Veterans' Hospital No. 27.

Case Illustrating Digital Compression of the Vertebral Arteries for Pulsating Tinnitus —Sir J. Dundas Grant, K. B. E., M. D.

Woman 51. Low pitched, pulsating tinnitus was diminished by compression of the vertebral arteries in the sub-occipital triangles, pressure being effected by the thumb and middle finger of the observer's left hand, while with the right, counter-pressure was exercised on the forehead. Menopause, four years previously, and patient complained of flushes of heat. Blood-pressure, 150. She was relieved by potassium bromide and magnesium sulphate. Tinnitus assumed to be due to a neuro-vascular arterial congestion of the labyrinth.

Discussion.

Mr. Sydney Scott had always doubted whether the vertebral artery could be compressed on the suboccipital region.

Mr. J. S. Fraser thought that most cases of tinnitus could be attributed to neuritis of the cochlear nerve, or to affection of the cochlear ganglion cells.

Dr. P. Watson-Williams thought that the usefulness of this test could be easily exaggerated, and its value as easily minimized. He doubted if the vertebral arteries were really compressed, but in some cases Dr. Grant's seemed to arrest the tinnitus. To differentiate middle and internal tinnitus one could compress the corresponding carotid; if of middle ear origin the tinnitus would be diminished, most likely, but would be unaffected, or possibly made worse, if from the internal mechanism.

Sir J. Dundas Grant, in reply, said that in 1887, in order to be sure that pressure acted on the vertebral artery, he had practised it on the cadaver. He exposed the artery, in the lower part of the neck, fixed a syringe in it and injected water. The outflow through the cut end of the basilar artery was completely stopped when the pressure method was exerted. In a living patient it is not likely that the lumen would be so completely obliterated as to cause danger. When this pressure checked the tinnitus it shows that it is congestive, as in many climacteric changes. The bromides in some form would likely be beneficial. Such pressure might be useful in the diagnosis of vertebral aneurism.

In reply to Mr. Somerville Hastings, Dr. Grant suggested that the congestion was in the region most directly supplied by the internal auditory artery, a branch of the basilar which was formed by the two vertebrals. In congestive middle ear disease improvement of the tinnitus might be expected by compression of the carotid. He advised testing the vertebrals first and later the carotids, since the former had no large companion veins associated with them, and the result more emphatic than with the carotids.

Case of Cerebral Abscess as a Sequel to Acute Otitis Media, Which Had Completely Healed—E. H. Richards, M. B., B. S.

Boy, QY. Acute otitis. Media, left. May, '23, paracentesis. Recovery with normal hearing, followed by headaches over left side. Eight weeks after the otitis admitted to hospital with severe headaches, vomiting, irritability, optic neuritis, diplopia, and sensory aphasia. Some weakness of left rectus (external), bilateral papilloedema, and some spontaneous nystagmus to either side. Hearing was normal and labyrinths reacted normally. From the presence of the sensory aphasia diagnosis of abscess was made and operation performed. No signs of disease in mastoid orantrum. Swabs proved antrum sterile. Dura of middle fossa indicated increased tension.

Exploration of spheno-temporal lobe revealed an encapsulated abscess separated from the surface by 8/2 in. of apparently normal brain. Abscess contained 8 oz. or more of odorless pus, from which a pure culture of streptococci was grown. Drainage with a tracheotomy tube only, for twenty-four hours, and uninterrupted recovery.

Discussion.

Mr. Sydney Scott (President), says this case reintroduced the subject of drainage of brain abscess, as well as other interesting points, such as the signs of brain abscess after the original infection had resolved. Mr. Scott had seen such cases, in one of which an enormous brain abscess formed, filling the whole temporo-sphenoid lobe, and extending back into the occipital lobe, the symptoms of which arose after the acute suppurative otitis media had completely disappeared, without operation.

Two Cases of Chronic Suppurative Otitis Media, Treated by Ionization—A. R. Friel, M. D.

(1) Male, 16. Aural discharge for many years, persisting in spite of drops. When he first presented, there were granulations on the posterior wall of right ear, at junction of tympanum and meatus. Aspiration with Siegel's speculum brought foetid pus. The essential points in treatment of the case were destruction of the by zinc electrolysis and nitrate of silver, followed by zinc ionization of the cavity from which the pus emanated. The distribution of the current to the cells in sufficient amount was effected as follows. A few inches of fine silk-covered copper wire were doubled and twisted. The twisted portion, slightly over an inch long, was fastened to a handle. It was then, together with the lower part of the handle, dipped in a warm solution of zinc salt thickened with gelatine, and then hung vertically, so that a small blob of gelatine collected on the tip. When dry the twisted wire, except the very tip, was painted with shellac varnish. When the patient was ionized, one of the free ends of the wire was attached to the positive pole of the rheostat, while the end of the twisted portion was insinuated into the narrow opening of the cell after it had been filled with a few drops of zinc sulphate solution. The silk and gelatine prevented a short circuit onto the tissues, and the shellac varnish prevented the current from being dissipated in the meatus and tympanum.

Discharge has ceased.

(2) Male, 23. History of aural discharge for more than four years. Examination revealed attico-mastoid disease, with foetid discharge, and cholesteatoma, also plypus and granulations in the tympanum. Treatment as follows. Portion of outer wall of attic was destroyed by electrolysis, remains of mallus and incus removed, and mastoid antrum treated with zinc ionization. The disease within the tympanum treated with zinc electrolysis and nitrate of silver, zinc ionization and bracic powder.

Ear has remained dry for several months.

Discussion.

Dr. W. Hill thought many were sceptical of this method of Leduc's. The selected cases which he had sent to Dr. Friel there had been only one failure, and in two there had been granulation. Dr. Friel did electrolysis first, ionization later. Success depended on very careful technique. Dr. Hill admitted his own scepticism at first. The granulation cases had all stopped suppurating, a very important matter, especially with children. Recurrent furunculosis of the meatus had also been arrested by Dr. Friel.

Dr. T. B. Jobson said the destruction of the outer attic wall by electrolysis was a new and original idea, and might lead to a great advance in the treatment of attic cases; the cure of them without the destruction of hearing.

Mr. Somerville Hastings wished to know how often Dr. Friel had destroyed the outer attic wall by electrolysis. It seemed to him a dangerous process to remove bone by causing necrosis, and he considered the area ominously near the meninges for removal by necrosis.

Dr. Friel, in reply, answered that he had carried out the proceeding seven or eight times, mostly on children, out-patients. He had adopted local anesthesia, novocaine into the posterior wall, at junction of cartilaginous and bony parts. He used one or two dry cells to furnish current to the apparatus.

Simulation of Malignant Disease of Middle Ear by Cholesteatoma with Fibromatous Changes—Dan Mackenzie, M. D.

Woman, 60. Old standing discharge from right ear, with complete facial paralysis of recent manifestation. External meatus occupied with granulations, infiltrated, and view of tympanic region obstructed. Arching over the attachment of the pinna in temporal region, also a hard semi-circular mass just under the skin, extending down as far as the tragus. Acting upon these appearances the parts were opened up, by a large incision, so devised as to include the auricle in a large flap hinged forward like a door. The hard mass was expeditiously removed entirely. It extended from a cholesteatomatous cavity in the mastoid process around the temporal region as far as the preauricular gland. In the mastoid process itself old cholesteatoma and granulations were found, but no evidences of neoplasm. Meatal walls ulcerated and ragged. Facil nerve was not encountered. Laboratory report, no indications of malignancy discoverable. The fibrous mass contained fibromatous material and gland tissue.

Discussion.

Sir J. Dundas Grant suggested that this was a genuine case of cholesteatoma, as distinguished from the post-suppurative cholesteatoma so frequent.

Case of Lupus of the Lobule—Arthur H. Cheatle, C. B. E., F. R. C. S.

Woman, 64, presented at King's Hospital, with a pear-shaped tumor, hanging from the lobule, forming for two years. Dusky and soft, with no ulceration of the skin, which was smooth. Behind the auricle, just above the tumor attachment was a small apple-jelly spot. No evidences of lupus or tubercle elsewhere. No history of injury. Tumor and nodule were removed in one piece, and skin sutured. Laboratory report, nodules of granulation tissue and few giant cells. Politzer refers to a similar case reported by Niesser.

Discussion.

Mr. J. S. Frazer said in a similar case of his own the patient had worn ear-rings, but the one in question had never done so. She attributed the trouble to a warty growth, which she scratched and infected.

Facial Paralysis Associated with Actiomycosis, and Simulating a Bezold Mastoid Abscess
—J. F. O'Malley, F. R. C. S.

Male, 67. History of mosquito bite the beginning of August, '23, near right ear, followed by a large swelling and inability to move his face. August 15, '23, seen by Dr. Verbrugge, temperature 101.5 F., which persisted for five days. Swelling prominent below ear, extending on to mastoid and parotid region. August 21, '23, swelling incised releasing pus, which has flowed ever since.

November 1, '23, seen by exhibitor, who, taking into consideration the mastoid infection, suggested actiomycosis. Slides were shown with mycelium.

Preventable Mortality from Diphtheria

The *Health News Service,* published by the New York State Board of Health, calls attention to the fact that a large percentage of the deaths from diphtheria occurring in New York state need not have resulted is the inevitable conclusion to be drawn from an analysis of the first 500 such deaths in 1923, made by Dr. Bertrand E. Roberts, epidemiologist of the New York State Department of Health, the results of which were recently published in the *New York State Journal of Medicine.*

Dr. Roberts points out that delay in the administration of antitoxin is the greatest cause of death from diphtheria, stating that if it is administered in adequate dosage on the first day of the disease, with proper surgical treatment in laryngeal cases (membraneous croup), recovery nearly always takes place. In the series of cases analyzed, in only 15 per cent of them was a physician called on the first day of illness, and in only 32 per cent was a physician called on the first or second day, leaving more than one-half in which there was lack of medical attention until the third day or later. Such delay is, of course, the fault of parent or guardian. However, the physician is not altogether blameless for the delay in administering specific treatment; this is shown by the fact that in about 40 per cent of the cases the doctor did not give antitoxin at his first visit, and in 53 cases, or 11 per cent of the total, antitoxin was not given at all. In some cases of doubtful diagnosis, seen on the first day of illness, there may be some excuse for delaying treatment until confirmation of the diagnosis is secured from a laboratory. Such a condition of doubt is rare after the first day, yet there were 159 instances in which a physician did not see the case until the second day of the disease or later, but in which he waited at least one day longer before giving antitoxin. According to Dr. Roberts it is unjustifiable to delay treatment while awaiting a laboratory report on a culture if there is even a suspicion that the patient may be suffering from diphtheria. Even if one could get an immediate laboratory report, it is never safe to rely upon it to disprove the diagnosis of diphtheria, for in this series of fatalities there were negative first reports in 15 per cent of those from which laboratory data were available.

Another cause for fatality emphasized in this report is insufficient dosage of antitoxin even though the case was seen early. Of 161 patients seen by a physician on the first or second day of the disease, only 57 received a possibly adequate dose of antitoxin. Dr. Roberts states furthermore that antitoxin for remedial uses should always be injected either directly into the veins or deep into the muscles and not just under the skin, the effect being from four to ten times as rapid by the former methods.

Three hundred and thirty-six of these 500 deaths were due either to interference with breathing (choking to death) from laryngeal involvement or to heart complications; that early use of antitoxin in sufficient dosage will prevent these complications is well-known to the medical profession. The remaining 164 deaths were due to one or more of various other complications, most of which are similarly preventable. The deaths due to heart complications are not infrequently due to failure to keep the convalescent patient at rest, usually contrary to the physician's orders.

In the opinion of Dr. Matthias Nicoll, Jr., state commissioner of health, "this analysis of diphtheria deaths tends to confirm the conclusion of previous observers that the death rate is practically nil when adequate treatment is given on the first day of the disease. The number of deaths from this disease will be enormously reduced when parents are brought to a realization of their responsibility to secure prompt medical attention whenever one of their children suffers with a sore throat or croup, and when every physician administers antitoxin in sufficient dosage whenever there is the slightest suspicion that a child has diphtheria."

CLINICAL DIGEST

A concise epitome of current literature, brief reports of clinical cases, and other items of clinical interest. Our readers are earnestly invited to contribute freely to this department, so that it may be of the widest and most vital usefulness.

EYE

Conjunctival Infection with Tubercle

In 1913, remarks the *Lancet*, A. Calmette and his fellow workers drew attention to the possibility of infecting guinea-pigs with tubercle bacilli by the conjunctival route, and it was thought that a clue had been found to the genesis of the cervical adenitis of childhood. Though the virus transmitted through the conjunctivæ spread to the cervical glands, the tracheo-bronchial glands, the lungs, and abdominal viscera, lesions at the level of the eye itself were never observed. We alluded briefly last week to similar investigations conducted by Prof. S. Lyle Cummins with results that did not in every respect tally with Calmette's. Prof. Cummins found that a definite local inflammatory reaction in the eye itself usually occurs but is very late in appearing. Of two guinea-pigs infected by the conjunctival route, one (No. 125) was a normal animal, and the other (No. 123) had been inoculated a month earlier with tubercle bacilli of low virulence. In this animal acute conjunctivitis developed a day after the conjunctival instillation, whereas in the case of No. 125, the conjunctivæ did not become inflamed until the third week after the instillation. It would seem that the rapid onset of acute conjunctivitis in the animal already infected with tubercle bacilli of low virulence was due to an allergic state induced by the earlier infection. Comparisons made between the effects of subcutaneous injection and conjunctival instillation of tubercle bacilli brought out one very interesting point. Among the guinea-pigs given subcutaneous injections of varying quantities of tubercle bacilli, there was no appreciable difference in the reaction, whether 2,000 million or only 2,000 bacilli were injected. But when the bacilli were introduced by the conjunctival route, the course of the disease varied according to the dose; it was rapid and acute when a concentrated emulsion of tubercle bacilli was instilled, and chronic when dilute instillations were given. These observations give support to the hypothesis that in the tuberculosis of man the massiveness of infection plays an important part. The condition of the child whose only apparent defect consists of enlarged cervical glands may be compared with that of guinea-pig No. 125 which seemed to be in excellent general health six months after conjunctival infection. When killed it was found to have lesions strictly limited to the infected eye and the cervical glands, which were fibrotic and contained limited areas of caseous degeneration. Prof. Cummins suggests that artificial per-conjunctival infection should help to elucidate many of the phenomena of tuberculous infection and resistance, although the constant association of eye lesions with the cervical adenitis in guinea-pigs indicates that the tuberculous processes in the guinea-pig and man are not strictly similar. And his suggestion is worth following up.

Retinal Thrombosis

Allen Greenwood, in the *Journal* of the American Medical Association, states that the prognosis, as far as the eye is concerned, depends largely on the stage at which the patient comes for treatment. If the case is seen early enough, it is possible, by proper treatment, to bring about a considerable measure of restoration of vision, even in some of the cases that appear hopeless from the clinical picture. If, however, the obstruction has been present more than a few days, and there has been no return of circulation, there is little hope of restoring the vision, and in many cases a secondary glaucoma develops, which usually demands a prompt enucleation.

De Schweinitz says, "If the thrombosis is in the central vein, hope of restoration of vision practically must be abandoned; in obstruction of a branch the prognosis is more favorable."

Some authors have tried to prove that the occurrence of the thrombosis of the central vein, or of one of its branches, has some value as a prognostic indication of the general length of life of the patient affected. The author has not found this true, and does not think that the retinal apoplexy in any way portends early death from circulatory causes. One cannot prognosticate except in a general way in a patient with arteriosclerosis. Neither can one prognosticate from an endophlebitis with thrombosis.

In the opinion of Coats, thrombosis of the central vein affords very little information with regard to the prognosis for life.

Geis, in a paper on retinal hemorrhagic and vascular disease as related to the condition of cerebral vessels, reported that he investigated for five years, or until death, the clinical history in a number of cases of venous thrombosis, and found that in from 40 to 50 per cent this was a forerunner of vascular sclerosis of the brain,

which, in some cases, did not become evident until after nine to twelve years.

Treatment.

It is advisable to have such cases under the care of a general physician, who will see that the bodily functions are as nearly normal as possible, particularly in view of the fact that there is so commonly an accompanying general angiosclerosis. In considering the treatment of the condition itself, there are two objectives to be sought: (1) The restoration of vision as far as possible or the prevention of an increase in loss of vision, and (2) the prevention of a subsequent glaucoma. As pointed out under prognosis, the treatment, to be of any value toward restoring vision, must be early, and any measure which an ophthalmic surgeon feels may help to restore circulation should be adopted. Greenwood has usually tried fairly frequent inhalations of amyl nitrite and the giving of some form of nitrite internally to keep up the effect of the inhalations. The withdrawal of fluid from the circulation by pilocarpin sweats and mild purges has also been adopted in suitable cases. For long continued treatment, some of the iodin preparations have seemed to be useful. The author has been in the habit of keeping such patients on small doses of syrup of hydriodic acid over long periods. The tension should be taken frequently, and if that in the afflicted eye is higher than that in the opposite, myotics should be used. It is his custom to use myotics in such cases as a routine measure, even if increased tension is not present.

De Schweinitz says that treatment "depends upon the general condition, and the patients with central vein thrombosis should be thoroughly studied from all standpoints and treatment directed according to the results of the examination. Other things being equal, iodids and syrup of hydriodic acid may be administered. Diaphoresis may be tried; mydriatics should not be used lest they cause glaucoma; indeed, it is proper to use miotics as part of the routine treatment."

EAR

Earache of Laryngeal Origin

Louis H. Clerf, in the *Journal* of the American Medical Association, states that patients with advanced cancer of the larynx, complaining of pain in one or both ears, are not uncommonly seen at the Bronchoscopic Clinic. Careful examination of the ears reveals no pathologic basis for the otalgia complained of. Because of its association with laryngeal cancer and pain radiating upward along the corresponding side of the neck, we have concluded that, in the presence of a normal ear, it must be of reflex origin from the larynx.

Patients complain bitterly of this distresing symptom, and resort to morphin or codein is necessary to give relief. Remembering the remarkable results obtained by Dr. Greenfield Sluder, who cocainized the nasal ganglion in earache of inflammatory middle disease origin and reflex earache after tonsillectomy, Dr. Chevalier Jackson suggested that this method be tried in these cases of reflex earache of laryngeal origin. Following is a brief synopsis of the records of two of the cases, with the results obtained:

Report of Cases.

Case 1.—A man, aged 44, was referred to the clinic by Dr. William Hitschler, with a provisional diagnosis of cancer of the larynx. The symptoms dated back about six months. For the last two months he had pain in both ears, which interferred with sleep. The diagnosis of cancer was verified by biopsy and, because of the extensive involvement, laryngectomy was advised. This was refused by the patient. The earache became progressively more severe, and was but slightly relieved by morphin. Cocainization of the nasal ganglion was done, with remarkable results. The relief from pain was complete within one-half minute, and did not occur for from eighteen to twenty-four hours, when cocainization was again done. The patient stated that "it acted like magic." He failed to return to the clinic after about two weeks. This was the first case in which our observation was made.

Case 2.—A man, aged 76, a physician, complained of hoarseness beginning four years before. When examined during July, 1921, there was an ulcerating growth involving the entire left side of the larynx, which was diagnosed by biopsy as cancer. Because of the extensive involvement, operation was contraindicated and radium was advised. This was applied by Dr. W. S. Newcomet. During July, 1923, the patient complained of severe pain in the left ear. This was associated with considerable swelling of the left arytenoid. Examination of the left auditory canal and drum membrane showed no pathologic changes. Cocainization of the left nasal ganglion gave immediate and complete relief. This was repeated every third or fourth day because of the recurrence of the otalgia.

Comment.

The results obtained by this procedure have been most gratifying. The relief is almost immediate, and is lasting. It is more efficacious than morphin, and is not followed by the ill effects that result from the frequent administration of that narcotic. The simplicity of the procedure makes it readily applicable. We now utilize it in all cases of reflex otalgia of laryngeal origin.

NOSE AND THROAT

Myxedema of the Larynx

E. M. Josephson, in the *Journal* of the American Medical Association, remarks that the characteristic voice of myxedema, which the clinician has for a long time recognized as a feature of the clinical picture of that disease, has aroused but little interest on the part of the laryngologist. It may be because the laryngologic phase of the disease ordinarily does not predominate the clinical picture, and because the disease is usually recognized in its early stages and is promptly and successfully treated, that there is no exhaustive study of it from the point of view of the laryngologist. Josephson is at present engaged in such a study, and would welcome any aid physicians might offer. Pathologic material—myxedematous and cretinous larynges—is especially sought for, but has not been obtained in sufficient volume.

The case here presented is of sufficient interest to warrant publication.

Report of Case.

History—A woman, aged 42, presented herself in February, 1923, with the chief complaint of orthopnea and a choking sensation in the throat, especially marked when lying flat on the back. Family history was of little interest. The father died of nephritis and the mother of pneumonia. Her previous history was limited to an operation for removal of fibroids of the uterus in 1910; the menopause came at the age of 35. The present illness dated back to 1913; since then the patient had had a thick voice and had been afflicted with intermittent hoarseness, unaccompanied by cough, which is especially marked in wet weather.

Early in January, the patient grew hoarser than she had been during the last ten years. This hoarseness persisted in spite of improvement in the weather, and steadily became more aggravated. She also was unable to sleep because of intense orthopnea and a choking sensation in the throat, most marked when lying flat on the back. Her condition grew progressively worse, until she presented herself for treatment.

Examination—The patient was obviously acromegalic and moderately myxedematous. The weight was 190 pounds (86 kg.). The features were pallid and heavy; the size of the face and head were increased; the features were moderately prognathous; the hands were spadelike; there was hypertrophy of ears, nose and eyelids; the hair was coarse, dry, harsh and thickened; the tongue was greatly hypertrophied. There were fatty subcutaneous pads. The heart and lungs were negative. The general examination was otherwise of no special interest.

Laryngoscopic examination was rendered difficult by an extremely enlarged tongue that filled both mouth and pharynx. Below a large, well developed epiglottis was a mass of tissue springing, apparently, from the posterior wall of the larynx and the interarytenoid space, shutting off the view of the lower structures. This mass was deep red, and seemed to be ulcerated. Though it resembled tuberculous granulations and suggested the possibility of a neoplasm, a diagnosis rendered plausible by the similitude of metastatic glands offered in the submaxillary pads, the patient's appearance favored neither diagnosis. The sputum and Wassermann reactions were negative. It was not found possible, because of the enlarged tongue, to obtain a piece of tissue for biopsy by either direct or indirect method.

Treatment and Course—Thyroid therapy was resolved on; progressively increased doses were given, beginning with one-half grain (0.0324 gm.) of the dried gland once a day, up to 2 grains (0.13 gm.) of the extract three times a day. Within two weeks, the symptoms complained of disappeared completely. Laryngoscopic examination now showed a very large larynx, supermasculine in its proportions, set deep in the throat. The mucosa was thickened, of a lighter hue than normal, and coarsely plicated over the arytenoids and posterior wall. The left cord was hidden from view by a prolapse of Morgagni's sinus. Marked thickening of the laryngeal wall left a diminished lumen. Under continued thyroid therapy the tissue of walls and prolapsed ventricle dwindled, leaving a spacious glottis and supraglottic regions. When the prolapsed ventricle had become reduced to a minimal size, an attempt was made to remove the prolapsed tissue by direct and indirect methods. The size of the tongue, though considerably reduced, interfered with successful operation, and it was not deemed necessary to attempt to operate under general anesthesia or by laryngofissure, because the patient breathed unobstructedly. An interesting phase of the treatment was the steady improvement in volume of the voice, parallel to the diminution in size of the tongue, and in its pitch and timbre paralleled to the laryngeal improvement.

Comment.

The improvement in the patient's condition is maintained throughout the period of thyroid therapy; but when occasionally it must be discontinued because of toxic manifestations, the patient's laryngeal condition relapses. The markedly hypertrophied lingual and faucial tonsils have been removed, in order to avoid irritation from those sources.

Respiratory Infections

Smiley, in the *Journal* of the American Medical Association, presents the following conclusions:

1. Tobacco, dust, gas, mouth breathing, sleep, drafts, constipation, perspiration, bathing and footwear are apparently not major factors in determining resistance to respiratory infections in this particular group.

2. Exercise appears as a liability rather than an asset in this group (probably because of improper care of the body in the stage of fatigue following the usual violent sport).

3. The use of woolen underwear is apparently no panacea for the prevention of "colds"; in fact, it seems almost safe to infer that the use of light underwear is preferable under conditions obtaining at Ithaca.

4. Heredity may be a factor in determining resistance through carrying on to the next generation a "catarrhal diathesis" or the opposite.

5. Since removal of nasal obstructions and diseased tonsils in more than half of the "four or more" group has not resulted in the reduction of the frequent "colds," it seems fair to conclude that nasal obstructions and diseased tonsils are not major factors in the majority of persons suffering with frequent "colds."

6. Of all the factors listed, only one (that of underclothing) showed a difference of more than 15 per cent in the two groups, and that only 19 per cent. It might be concluded, therefore, that, though underwear is of some importance, no major factor has been dealt with in the whole questionnaire.

What the major factors in susceptibility to "colds" are is, therefore, as far as the work at Cornell University is concerned, still a matter of conjecture. There is an inclination toward the supposition that there is a specific lack of immunity in certain persons to the organism or organisms that cause "colds"; but until the etiology of these infections is definitely settled, a specific prophylactic cannot be looked for.

As a test of the prophylactic value of the present respiratory vaccines, a small number of the "four or more" group was inoculated once a month with one of the much used types of respiratory vaccines on the market, but no reduction in frequency of "colds" was noted in the majority of cases. Investigation along this line seems to offer some hope of success, however, and the therapeutic inoculation of a large number of patients, while they are suffering from "colds," will probably be attempted the coming year. The objective will be to prevent severity, prolongation and complication (so often caused by the known secondary invaders). On theoretical grounds, at least, such an objective is not impossible of attainment if the respiratory vaccines are considered capable of combatting the known secondary invaders; and if it is considered that the unknown virus itself (which we may assume is the true etiologic factor) is capable of running only a mild course.

Electro Cautery in Laryngeal Tuberculosis

Joseph B. Greene, in *Annals of Otology, Rhinology and Laryngology*, gives his technique as follows:

Technic.—In the use of the cautery I have largely followed the method of Wood, who has been a strong advocate of this form of treatment for a number of years. It is my custom to practice the indirect method, though I realize that skilled laryngologists, like Arrowsmith, Lynch, Dean and others prefer the direct method, using the suspension apparatus. It has seemed to me simpler and perhaps more comfortable to make the application by the indirect method, making it simply an office procedure. However, every well equipped sanatorium for the tuberculous should be equipped with a treatment room where patients in a weakened condition can be spared the exertion incident to a visit to the doctor's office. As to the anesthetic, will say that the pharynx and larynx are first sprayed with a 4 per cent cocain solution. The laryngeal applicator, well protected with cotton, is moistened with sterile water and then dipped into cocain flakes. The larynx is next thoroughly anesthetized, using at least three applications at intervals of several minutes. Inasmuch as every tuberculous larynx presents a different picture it is needless to say that it would be impossible to give a technic that would be suitable for every case. However, as a general proposition, would say that ulcerations require a superficial cauterization with a knife, and infiltrations, except within the larynx proper, require needle punctures. As a rule, it is better to be satisfied with not more than three or four punctures at one sitting. It is my custom to enjoin absolute silence for about a week after the use of the cautery, except where the epiglottis is being treated, returning gradually to the whispering voice. I frequently advise the use of cracked ice held in the mouth at frequent intervals for several days following the use of the cautery. It seems to lessen the reaction and add to the patient's comfort.

When you encounter an interesting experience in your work, or develop a new method, write us about it, that we may pass it on to the rest of the profession.

AMONG THE PROFESSION

Items of personal interest concerning the movements and doings of eye, ear, nose and throat men throughout the country, and of important happenings. Subscribers, please send us notice of interesting events in your locality.

A meeting of the Detroit Oto-Laryngological Society was held Wednesday evening, February 20.

The subject of the evening was presented by Doctor C. F. McClintic, professor and director of the Department of Anatomy, Histology and Embryology of the Detroit College of Medicine and Surgery.

His subject was entitled "The Vestibular Cerebellar Mechanism and Its Central Nerve Connections with an Explanation of the Syndromes of this Mechanism," from which the following was extracted.

A large attendance of the society was present.

Dr. McClintic emphasized the independence of the central nerve connections of the vestibular and cochlear nerves. He pointed out that the acoustic or cochlear nerve is characterized by its intimate connections with the cerebral cortex, whereas the vestibular nerve makes no connections with the cerebrum. That the connections of the vestibular nerve are entirely motor. He disproved by dissections and demonstration that the views of Fischer, Barany, and others that the vestibular nerve makes connections with the Pons. He shows that it does not. He shows conclusively that the primary connections are made with the medullary nuclei of the vestibular nerve and the spinal cord.

He further shows that the reflex connections of the vestibular nerve with the motor cranial nerve nuclei and the cord account for all the phenomena resulting from vestibular (semi-circular canal) disturbances, and that the cerebellum does not participate in the production of any of these phenomena. This is an entirely original view and the proof presented makes the conclusions logical and beyond question.

He also denies the existence of an eye center in the superior portion of the middle lobe (vermis) of the cerebellum and locates this center in the occipital lobe of the cerebrum and shows how the mistake of locating the center in the cerebellum can be accounted for.

Dr. McClintic corroborates his anatomical and physiological findings by a discussion and application of these facts to the signs and symptoms associated with cerebellar and vestibular disease.

His conclusions and findings do not alter essentially our clinical observations, but they do place the exp'anation of these clinical facts upon a new anatomico-physiological basis, and enable us to smooth out the point which others have explained by hypotheses more or less unsatisfactory and vague.

The discussion was profusely illustrated and supplemented by charts, lantern slides and dissections of the human brain stem.

Artificial Eye Experts at Milwaukee.

The artificial eye experts, Mr. Arno Kohler and Mr. Max Heinz, of New York, were stationed with their interesting equipment in the artificial eye department at the offices of the Milwaukee Optical Mfg. Co. on Monday, March 10th, and Tuesday, March 11th, making artificial eyes to order. Reservations and appointments were made by several of the specialists for their artificial eye patients, whereby the entire two days were completely filled up owing to the large number of persons desiring to take advantage of this opportunity in having artificial eyes made to order by these well-known experts. Several of the eyesight specialists and refractionists took occasion to visit the company's finely equipped plant and also to witness the making of the artificial eyes. The Milwaukee Optical Mfg. Co. has featured this special and interesting service annually for the past 10 years.

Laryngeal Epilepsy

Beaman Douglas, in *Annals of Otology, Rhinology and Laryngology*, reports the following case:

Mr. H., aged 59—always healthy except for attacks of laryngitis, usually coming on with the winter months. After a few weeks of coughing and hoarseness the attack would wear away, to be followed a year later by another similar one.

The patient was one of those possessing marked sensitiveness of the mucous membrane, which rendered all local examination and treatment very difficult. It was necessary at each treatment to completely cocainize the pharynx and larynx in order to make an examination and to give treatment.

In September, 1922, he appeared in my office from his country place and stated that he had suffered all summer from a troublesome cough and hoarseness. The cough, which was spasmodic in character, was worse at night, and sufficiently active to keep him awake.

An examination after cocainization showed a marked sub-acute pharyngitis and laryngitis. Heart and lungs normal, blood pressure 140, urinalysis normal and all other organs normal.

Subsequently a series of X-ray pictures confirmed these findings in the chest.

The coughing attacks were at first controlled fairly well by local treatment and small doses of heroin, but the patient did not make the usual recovery. The epiglottis seemed to be very much inflamed, was boggy, velvety and very red, and did not improve like the rest of the larynx and the pharynx. This thickened and inflamed epiglottis resisted all treatment and evidently was the cause of the coughing spells, which were frequent and severe.

Early in December the patient reported that he had fallen unconscious during a coughing spell—a fact which excited his family and himself very much. He was told to stay in his room, and now for the first time I had an opportunity to observe the "spells."



STOCO Heavyweight Frames

THE Stanrex and the Stanrite are the heavyweight leaders of the STOCO standard line of frames. The unusual bridge metal (the best you ever handled), the chiseled cut of the endpieces and the strong, unbreaking temple butts of these frames express the merit of STOCO craftsmanship, while the perfectly modulated lines and the rich color demonstrate the STOCO principle of making frames to gratify as well as to serve.

Manufactured by

THE STANDARD OPTICAL CO.

ESTABLISHED 1875 GENEVA, N. Y., U. S. A.

Makers of High Grade

FRAMES - MOUNTINGS - LENSES - OPTICAL MACHINERY

Please mention the Eye, Ear, Nose and Throat Monthly.

Specify

Semi-Finished KRYPTOKS

TELL your dispenser that you want your Kryptok prescriptions filled with Bausch & Lomb semi-Finished Kryptoks. You'll like the quick service he can give on these lenses, and the superb polish they have. As they are sent from the factory with the bifocal side finished, correct addition and proper segment size are guaranteed by us.

Bausch & Lomb Optical Co.

635 St. Paul St., Rochester, N. Y.

New York Washington Chicago San Francisco London

BAUSCH & LOMB OPTICAL CO. U.S.A. ROCHESTER, N.Y.

Please mention the Eye, Ear, Nose and Throat Monthly.

TWO WORTHWHILE BOOKS

Ophthalmoscopy, Retinoscopy and Refraction

Treat of Ophthalmology, Diseases of the Retina, Choroid, and Optic Nerve, Systematic Examination of the Eye, Glaucoma, Optical Principles, Test Type, Lenses, Refraction and Cycloplegics, Applied Refraction, Astigmatism, Presbyopia, Heterophoria, Retinoscopy, Measurement of Lenses, Prescription Writing, Transposition and Frame Fitting. By W. A. Fisher, M. D., F. A. C. S. **PRICE $2.50.**

Senile Cataract

describes clearly every detail of the methods of operation used by several of the world's greatest ophthalmic surgeons for senile cataracts. By W. A. Fisher, M. D., F. A. C. S. **PRICE $2.50.**

The Professional Press, Inc.
17 N. Wabash, CHICAGO

New Era Rx Service

1—Accuracy
2—Quick Action
3—Intelligent Execution
4—Prices That Save You Money

Reasons Why Our
Unexcelled Rx Department
Is Always Busy

Write for a patented P. D. Rule, Style EE — It is Free to You.

New Era Optical Co.
As Near to You as Your Post Office
17 No. Wabash Ave. Chicago, Ill.

When in Chicago Come and See Us

New Books of Real Value

The Tonsils

(Faucial, Lingual and Pharyngeal)

By **Harry A. Barnes, M. D.**, Instructor in Laryngology, Harvard Medical School; Laryngologist, Mass. Charitable Eye and Ear Infirmary; Laryngologist, Mass. General Hospital, Boston, etc. 2d revised edition. 217 pages, with 45 illustrations, mostly original. Price, cloth $5.00

This is a practical work on the tonsils. The new second edition has been completely revised and now includes all of the new operations as well as the old, which are described in great detail. The technic of local anesthesia has received special attention. The chapter on focal infections has been rewritten, and the section on x-ray and radium treatment of tonsillar hypertrophy is new. Many new cuts have been added. The posterior and lateral pharyngeal nodules are also described.

Tonsillectomy

By Means of the Alveolar Eminence of the Mandible and a Guillotine, with a Review of the Collateral Literature

By **Greenfield Sluder, M. D., F.A.C.S.**, Clinical Professor and Director of the Department of Laryngology, Rhinology and Otology, Washington University School of Medicine, St. Louis. 175 pages, 6½x9½, with 90 illustrations, mostly original. Price, silk cloth..... $5.00

Sluder presents for the first time his method of tonsillectomy by means of the alveolar eminence of the mandible and a guillotine. He has also reviewed the collateral issues, i. e., embryology, comparative anatomy, general human anatomy, physiology, pathology, clinical laryngology, and surgery. There is a special section on "Adenoidectomy with Direct Vision." The book is beautifully illustrated.

Ask for our new catalogue

C. V. Mosby Company
Medica Publishers **ST. LOUIS**

C. V. MOSBY COMPANY,
508 North Grand Blvd., St. Louis, Mo.
Send me the following books:

Barnes—Tonsils $5.00
Sluder—Tonsillectomy $5.00

Name .....

..... Lab. Jour.

Please mention the Eye, Ear, Nose and Throat Monthly.

J. E. KENNEDY & CO.

201 E. 23rd St. New York, N. Y.

Eye, Ear, Nose and Throat Instruments

Reese Model Keratome

A special broad Keratome bent at an angle of 21° with rounded angles. As used and recommended by Robert G. Reese, M. D., of the New York Eye and Ear Infirmary.

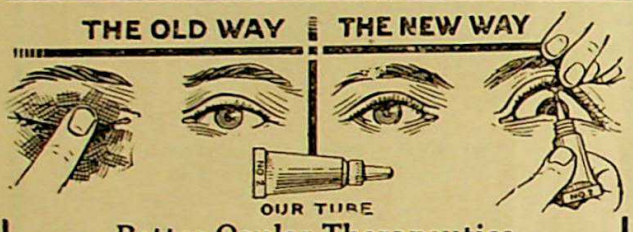

Better Ocular Therapeutics

Can be obtained by the use of "M-E-S-Co." brand of Ophthalmic Ointments. **Reasons: Selected Chemicals, Thorough Trituration, Perfect Incorporation, Sterilized Tubes, Boiled and Strained Petroleum, Excellent Service, No Waste, No Dirty Salve Jar, Right Prices.**

Write for complete information

Manhattan Eye Salve Co., Inc., Louisville, Ky.

OCULISTS ATTENTION

Our twenty years of actual experience in handling the most complex prescription work, is our guarantee of the best that is available.

Our aim is to interpret exactly what your Rx calls for.

Send Your Next Prescription to

G. & F. STANNARD CO.

Wholesale Opticians

141 East Fourth St. Cincinnati, Ohio

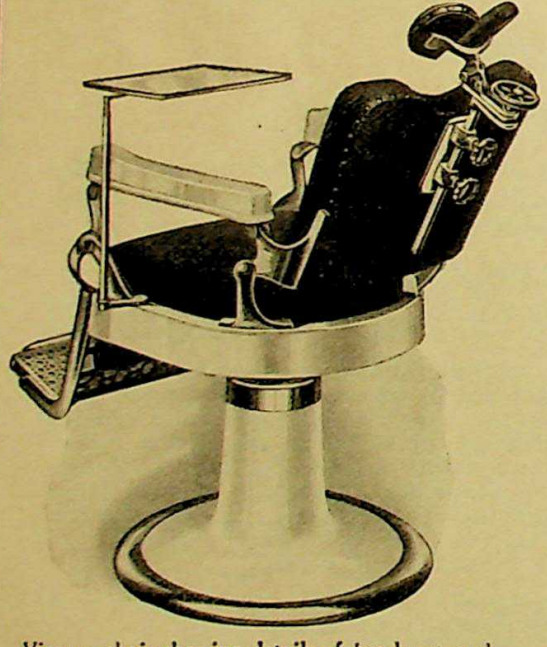

THE

"World's Greatest"

Eye, Ear, Nose and Throat Chair

is a confidence-inspiring piece of equipment

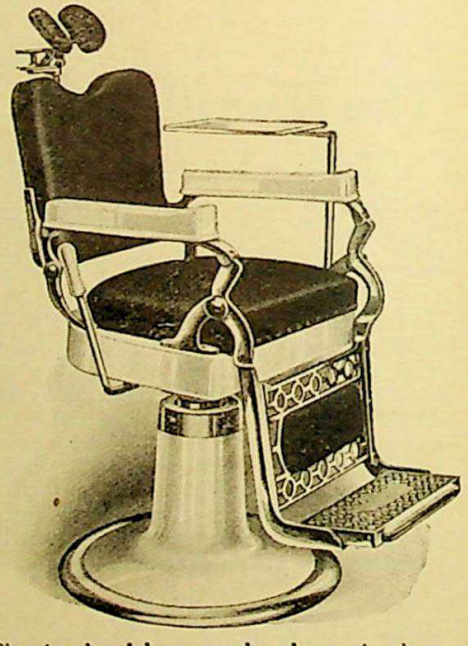

View o chair showing details of head-rest and instrument tray construction. Chair partly reclined.

Ask your dealer or send direct for circular.

Showing hand lever employed to raise lower. revolve and recline chair. 8½-inch raise obtainable. Can be reclined to horizontal position.

The Eugene Berninghaus Company, Cincinnati, Ohio

1872—Manufacturers Quality Products—1924

INDEX TO ADVERTISERS.

Abbott Laboratories, The 67
American Optical Co. ..... Back Cover
Baltimore Optical Co. 119
Bard-Parker Co., Inc. 66
Bausch & Lomb Optical Co. 116
Bay State Optical Co. 71
Berninghaus Co., The Eugene 118
Castle, Wilmot Co. 61
Dow Optical Co. ..... Inside Back Cover
Geneva Optical Co. 62
General Optical Co. 69
Hantover & Robinson Optical Co. 119
Kennedy, J. E., & Co. 118
Kloman Instrument Co. 66
Kohler & Danz 70
Kryptok Co., Inc. 72
Manhattan Eye Salve Co. 118
McIntire, Magee & Brown Co. 65
Meyrowitz, E. B., Inc. 68
Mosby, C. V., Co. 117
Mueller, V., & Co. 61
New Era Optical Co. 117
New Jersey Optical Co. ..... Inside Front Cover
Onepiece Bifocal Lens Co. 64
Physicians Supply Co. 70
Post Graduate Hospital & Medical School of Chicago 119
Riggs Optical Co. 63
Shur-on Optical Co. 120
Snugfit Eye Patch Co., The 119
Sorenson Co., Inc., C. M. 68
Standard Optical Co. 115
Stannard, G. & F., Co. 118
Tiemann, George, & Co. 63
Wilmot Castle Co. 61

THE SNUGFIT EYE PATCH

"Fitsany-head"
"Fitsany-eye"
"Fitseither eye"

Made in the Following Styles

	Per Doz.
No. 1 Black Silk covered Green Silk lined	$2.00
No. 2 Black Silk covered, Oil Silk lined	$2.25
No. 3 Black Silk over Black Buckram No lining	$1.50
No. 4 Black Buckram (no cover) Green Silk lined	$1.50
No. 5 Black Buckram (no cover) Oil Silk lined	$1.75
No. 6 Black Buckram (no cover) No lining	$1.25

All Snugfit Eye Patches are neatly bound with Leatherette binding. All have black silk strings.

THE SNUGFIT EYE PATCH CO.
Lansing, Mich.

Send Us a Sample Rx
We want to show you how!
A Real Rx House for the Better Ophthalmologists
HANTOVER & ROBINSON OPTICAL CO.
6th Floor, 30 North Michigan Blvd. - - - CHICAGO, ILL.
WHOLESALE ONLY

EYE, EAR NOSE AND THROAT MONTHLY
$3.00 per year
Let us have your subscription now

LENSES FRAMES Rx SERVICE EQUIPMENT
of
Quality—Skill—Service
Baltimore Optical Company
BALTIMORE WASHINGTON

Post Graduate Hospital and Medical School of Chicago

An entirely new feature of this institution is the Graduate Course of Instruction in OPHTHALMOLOGY and in OTO-RHINO-LARYNGOLOGY given to qualified physicians of medicine. A systematically arranged course for those wishing to become proficient in these specialties. Covering the entire subject including Laboratory, Experimental, Clinical, Didactic and Operative Instruction. Each course occupies one year divided into two terms of six months each. Now open for registration to a limited number.

For full particulars address

Dr. Otto J. Stein, Head of Dept. of Oto-Rhino-Laryngology or Dr. George F. Suker, Head of Dept. of Ophthalmology, or Superintendent, Post Graduate Hospital and Medical School, 2400 S. Dearborn St., Chicago, Illinois.

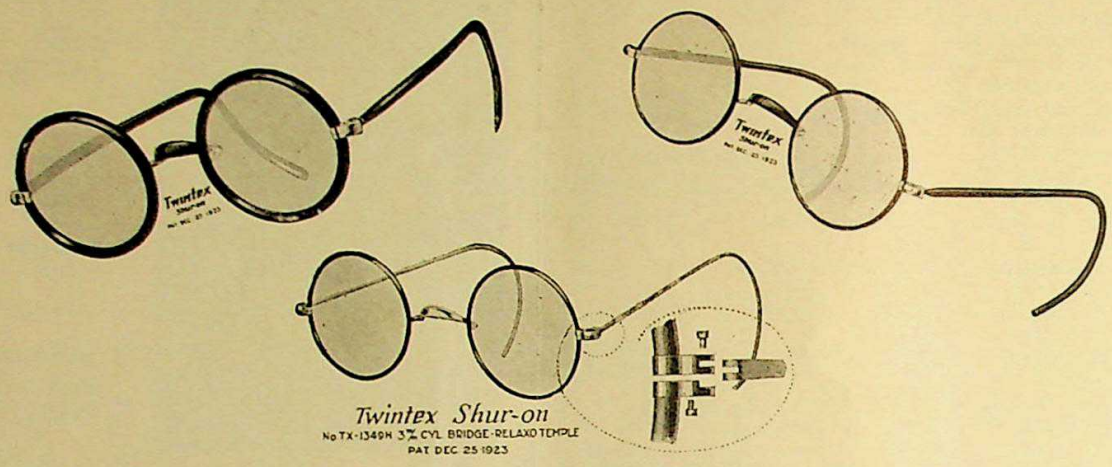

"—and use a Twintex frame"

which, without the slightest sacrifice of beauty and art, the strongest and sturdiest frame made—that it has an ingenious double grip, double brace, wabble proof end piece construction (an exclusive patented feature) which minimizes breakage—guarantees rigidity—insures longer life—more satisfactory wear and requires no repeated readjustments, for once it is properly fitted, it "stays put." I want my patients to get the most value for their money—so "use Twintex on my prescriptions whenever possible!"

Shur-on Optical Co., Inc.
Rochester, N. Y.

Specify Twintex on your Rx

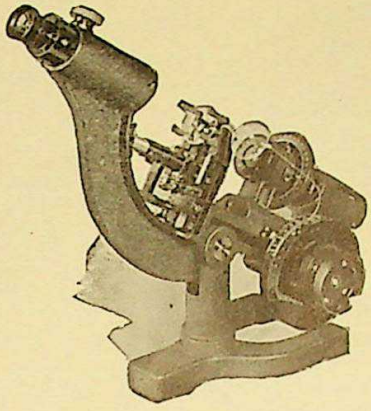

DEPENDABLE *Prescription* SERVICE

Verified on the Lensometer

Quality and durability are strikingly manifest in every product of the Dow Optical Company. Materials of the first quality combined with modern scientific methods of construction insure a product that will perform unfailing service.

Strict and accurate adherence to every detail of each prescription, by expert workmen, rightly justifies complete confidence in our work.

Practical and intensive cooperation as practiced by each member of our organization in the handling of prescriptions makes possible a quality and accuracy of service that insures permanent satisfaction.

DOW OPTICAL COMPANY

Thirty North Michigan Avenue, CHICAGO

W. E. DOW, President

Your Prescriptions are Accurately Filled

DEALERS IN OPHTHALMOLOGICAL INSTRUMENTS

382 W1/5

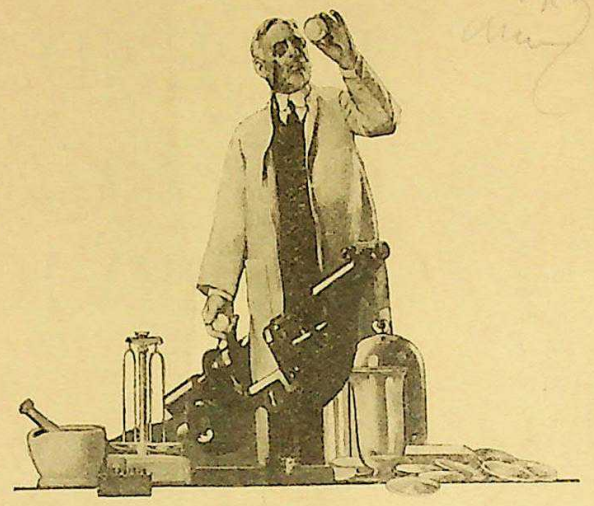

WELLSWORTH CENTEX

Scientific Accuracy Absolutely Assured

YOURS is one of the service stations to which comes the human machine for mechanical adjustment. And your reputation for quality service rests squarely upon the quality of merchandise—particularly the lenses—you use in your work.

Because of this fact, there is something about a Wellsworth Centex Lens that you should know, something underneath its physical appearance and surface indications with which you should be familiar.

You should know that every Wellsworth Centex, is first, absolutely accurate for focus; secondly, of scientifically accurate optical centers after the lens is edged. People must have confidence in your services and your merchandise. You can have full confidence in the accuracy of Wellsworth Centex Lenses.

American Optical Company Southbridge, Massachusetts, U.S.A.

WELLSWORTH
PRODUCTS
for Better Eyesight



All that Science can give:
all that Artistry can add